

# **The 26<sup>th</sup> TCTAP 2021 Virtual**

**Make a Difference with XIENCE and PCIO**

## **Benefits of OCT in PCI guidance and vulnerable plaque detection**

**Takashi Kubo**

**Wakayama Medical University, Wakayama, Japan**



# Disclosure statement of financial interest

Within the past 12 months, I or my spouse/partner have had a financial interest/arrangement or affiliation with the organization(s) listed below.

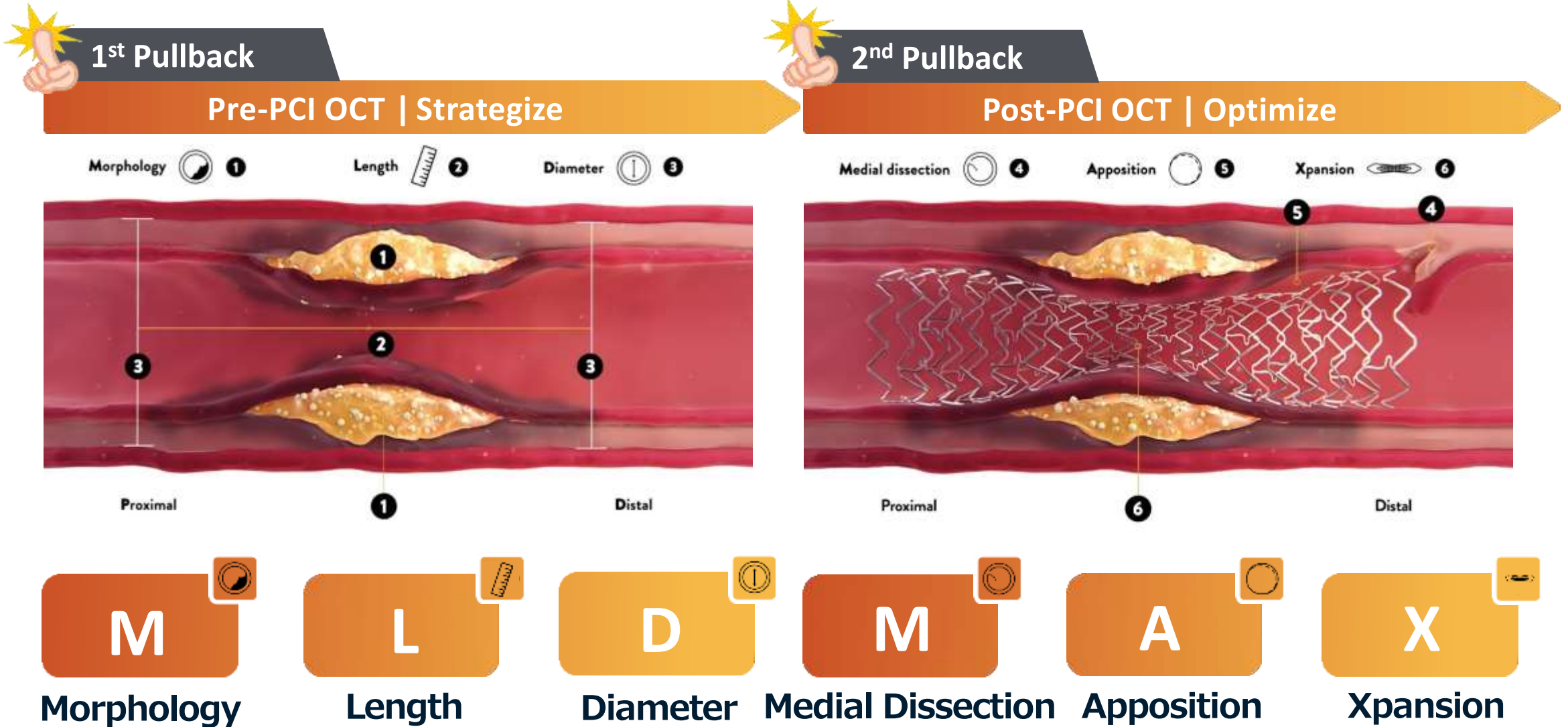
## Affiliation/Financial Relationship

## Company

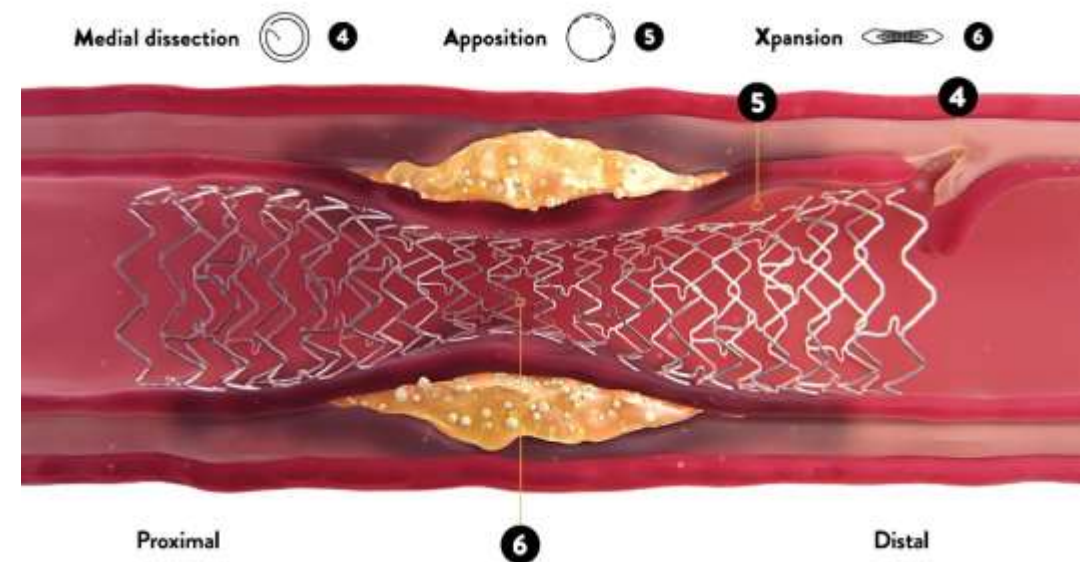
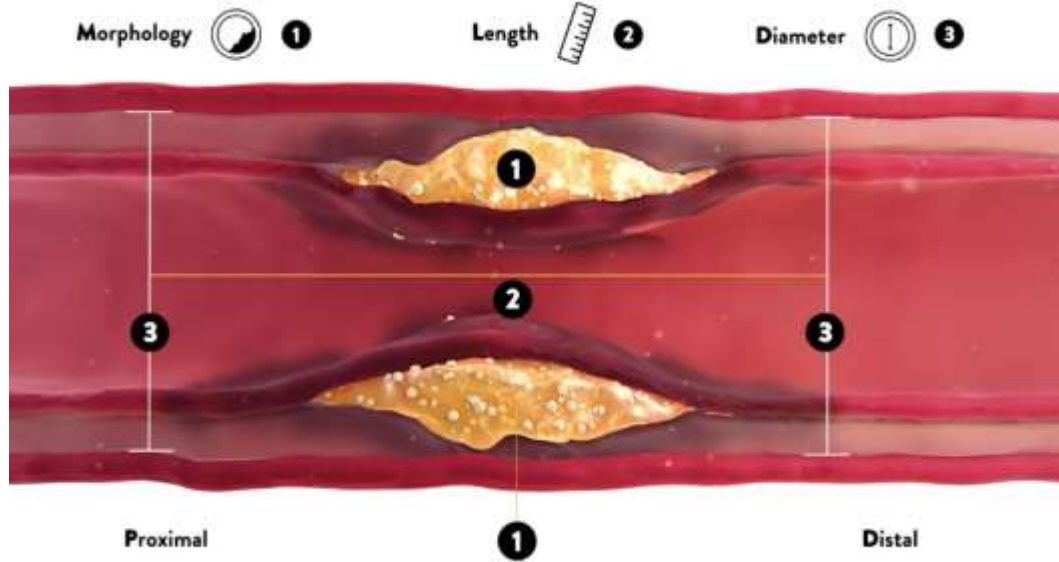
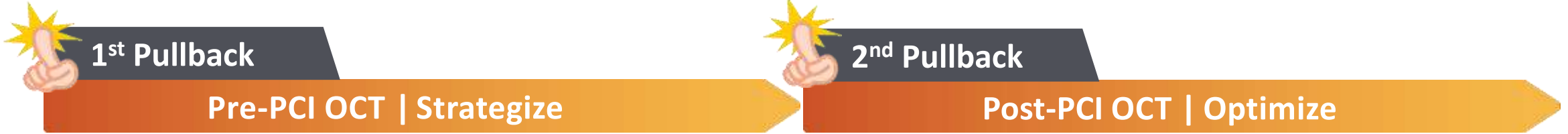- |                                  |      |
|----------------------------------|------|
| • Grant/Research Support         | • No |
| • Consulting Fees/Honoraria      | • No |
| • Major Stock Shareholder/Equity | • No |
| • Royalty Income                 | • No |
| • Ownership/Founder              | • No |
| • Intellectual Property Rights   | • No |
| • Other Financial Benefit        | • No |



# OCT-guided PCI algorithm **MLD-MAX** 2 Pullback



# OCT-guided PCI algorithm **MLD-MAX** 2 Pullback



**M**  
Morphology

**L**  
Length

**D**  
Diameter

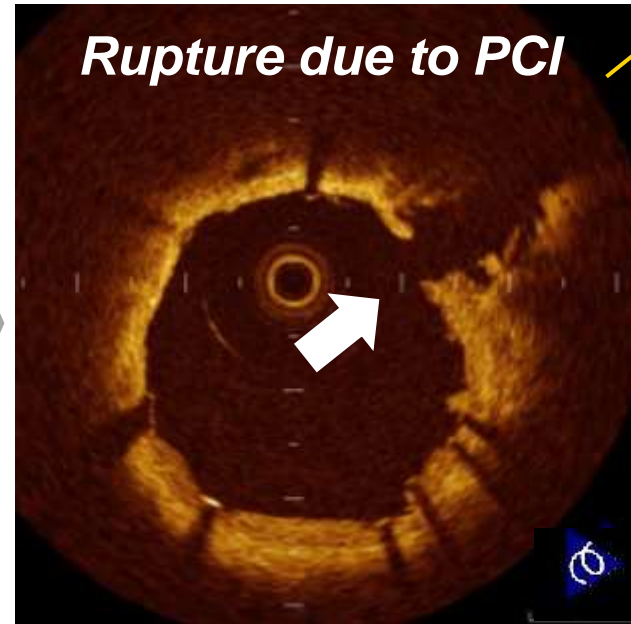
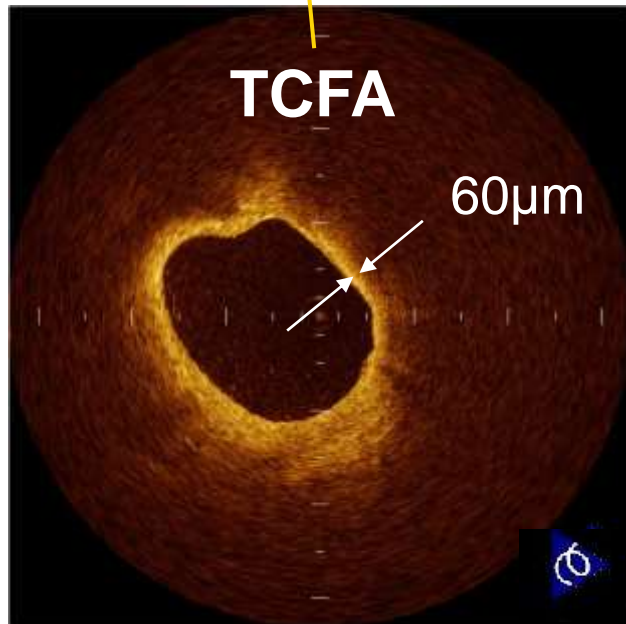
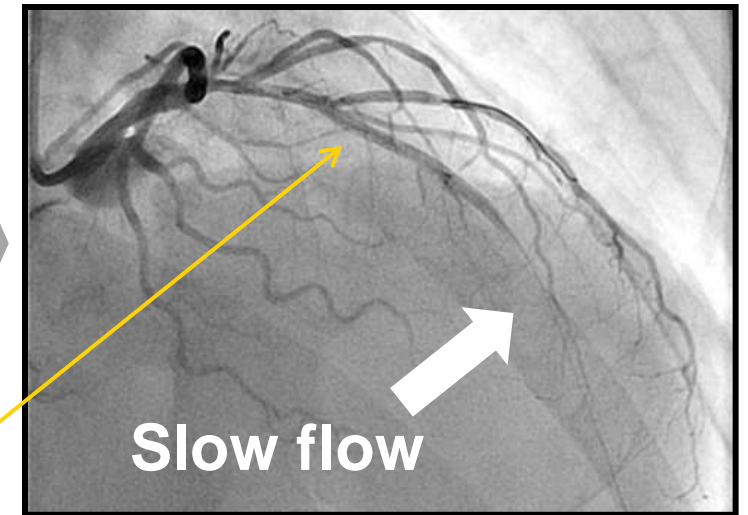
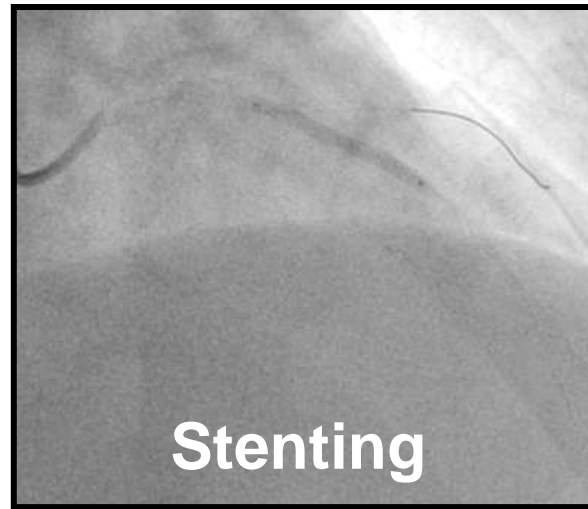
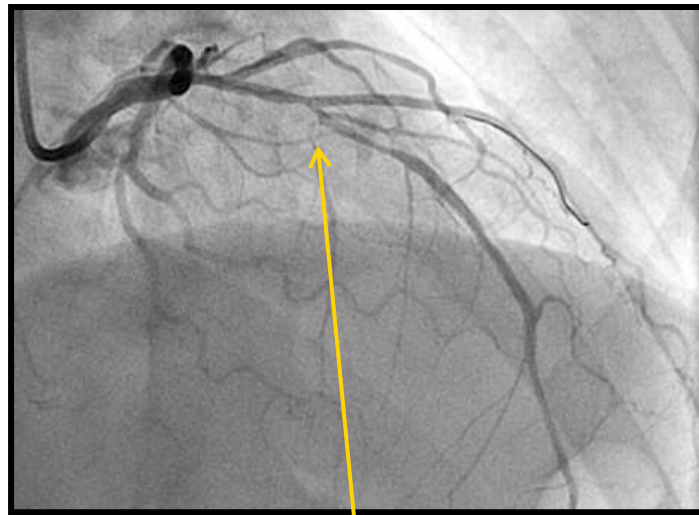
**M**  
Medial Dissection

**A**  
Apposition

**X**  
Xpansion



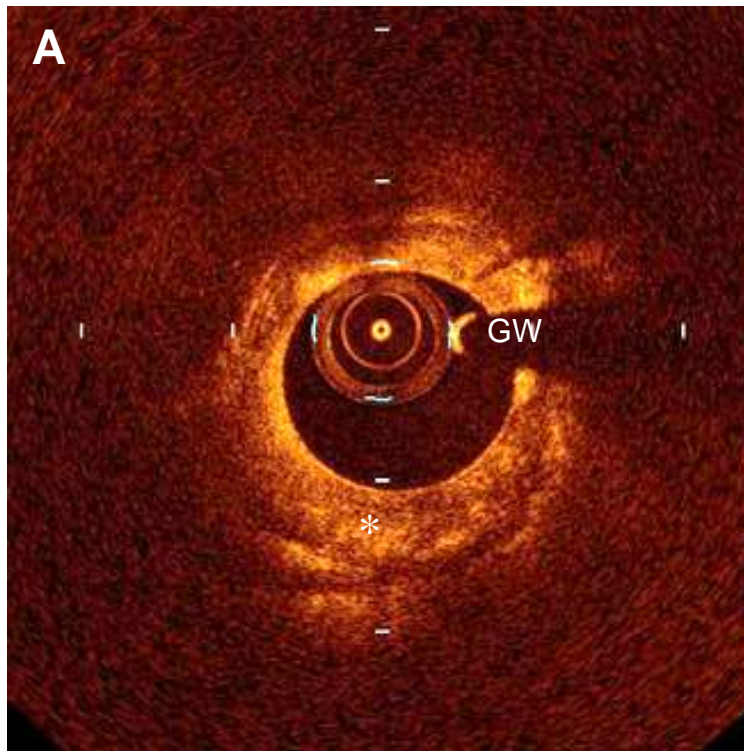
# Lipid rich plaque: risk of no-reflow



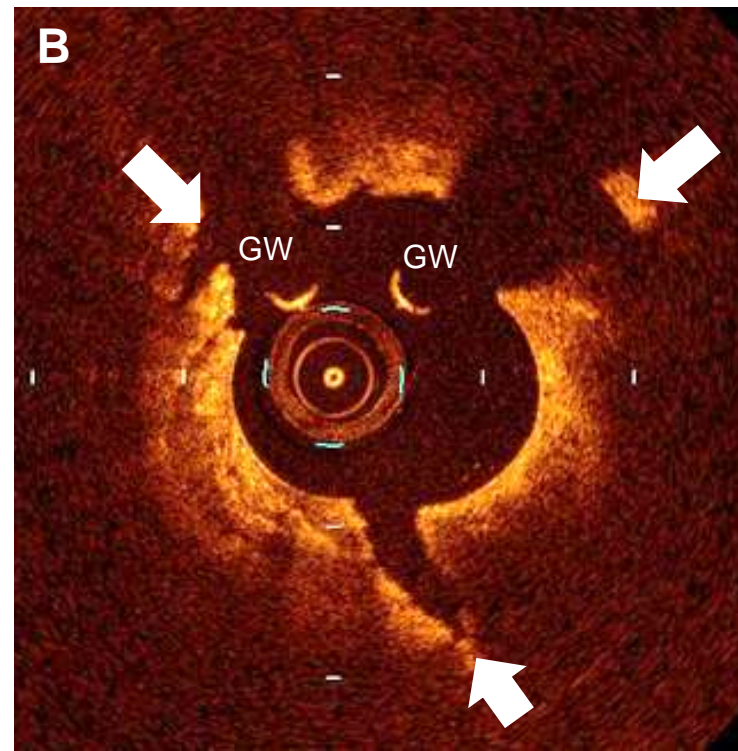
**A 73-year-old male** underwent PCI for the treatment of mid-LAD lesion (arrow). In OCT image at pre-intervention, the culprit lesion presented lipid-rich plaque with thin-fibrous cap. After stenting, angiogram showed no-reflow, and OCT disclosed plaque rupture behind stent. **TCFA is easy to be ruptured by PCI and has a high risk for coronary no-reflow.**

# Calcification: risk of stent underexpansion

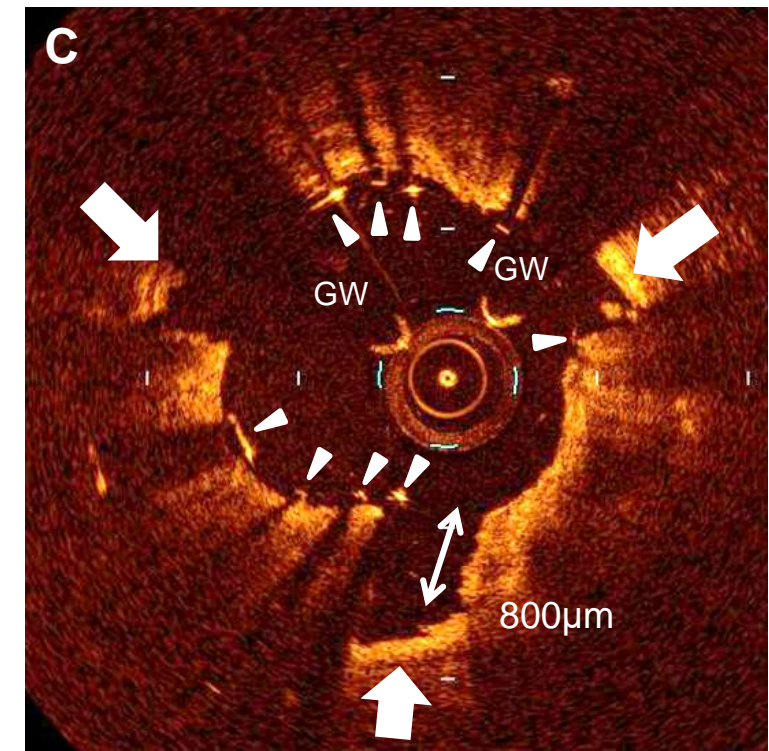
## Pe-PCI



## NSE (Non Slip Element)



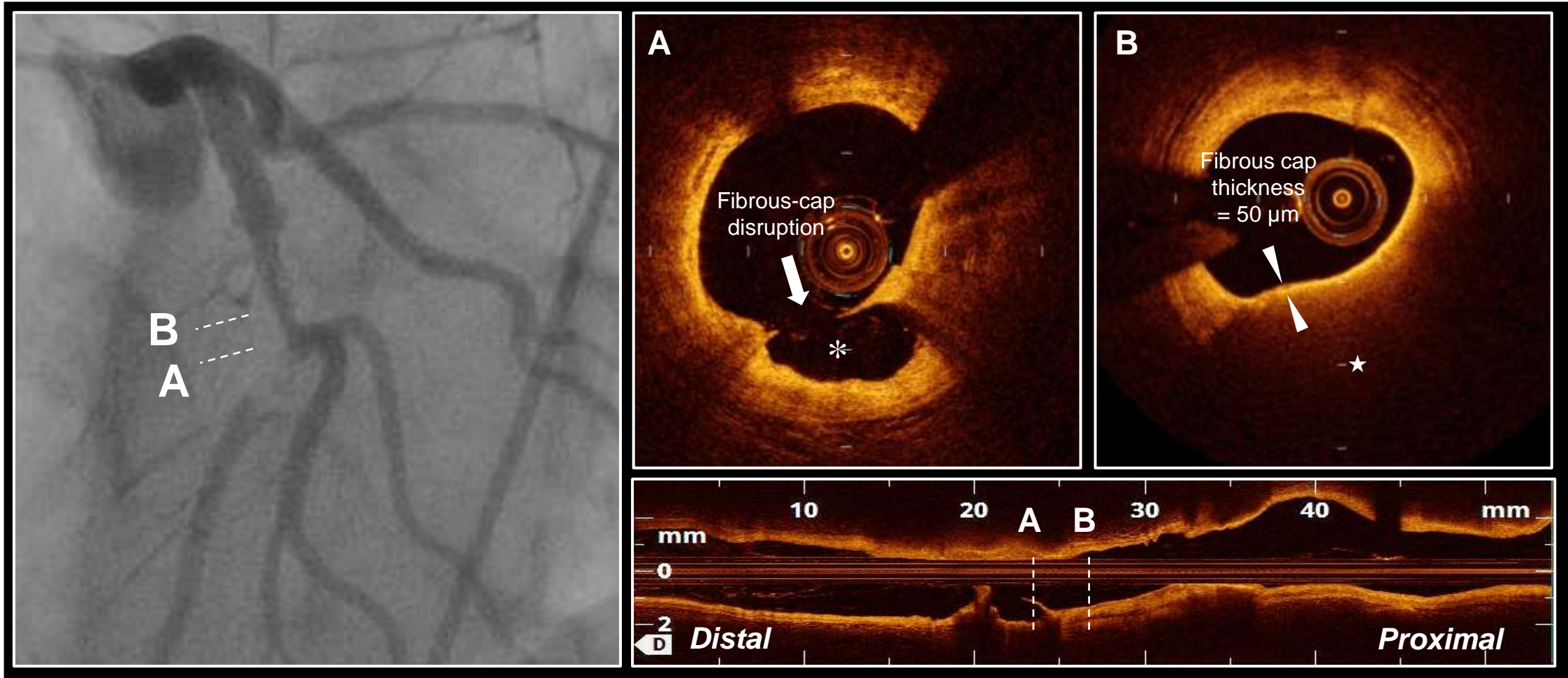
## Stent



OCT before PCI (A) showed entire circumferential calcium. OCT after NSE-balloon angioplasty (B) and after PCI (C) demonstrated calcium fracture (arrows). Thickness of the calcium fracture was 800µm (double headed arrow). Arrow heads = stent struts; Asterisk = Calcium; GW = guide wire.

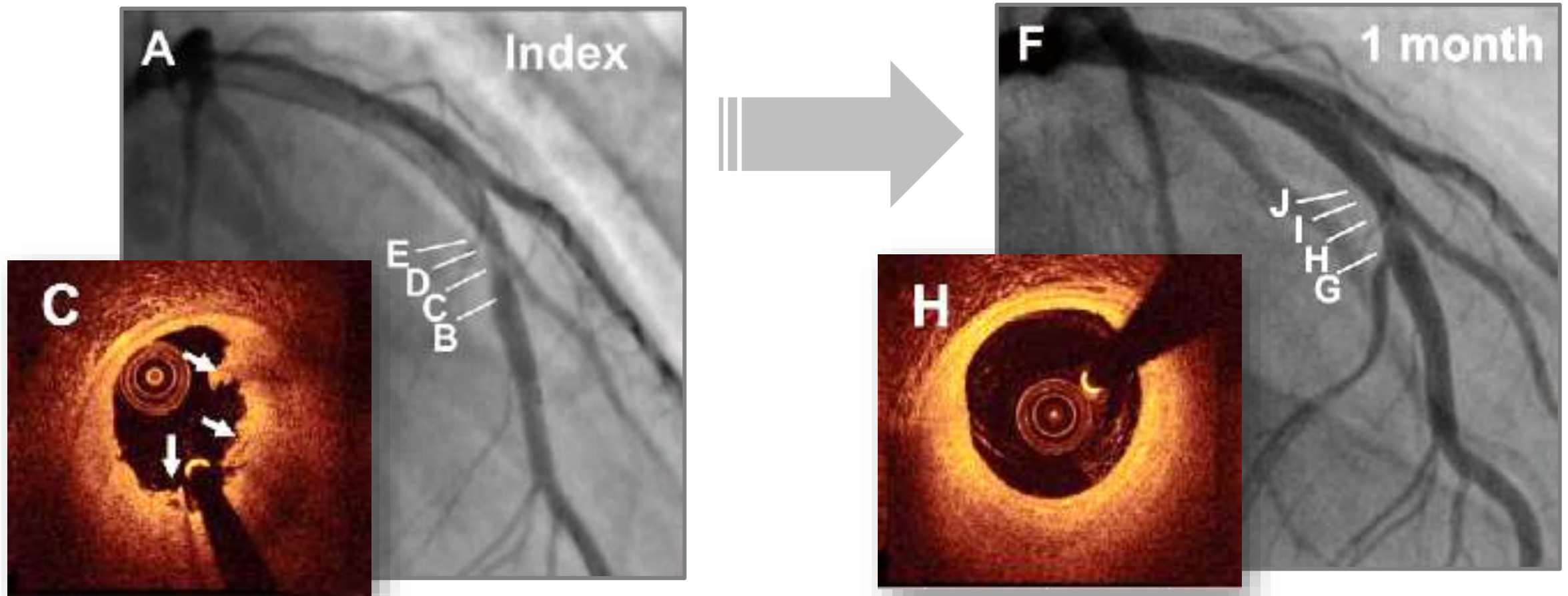


# Plaque rupture: risk of no-reflow



**Case: 72 years old female with STEMI.** Coronary angiography showed an occlusion in proximal LAD. OCT after aspiration thrombectomy demonstrated fibrous cap disruption (arrow) and core cavity (star) (A), and TCFA (fibrous cap = arrow heads, and lipid core = asterisk) (B).

# Erosion: non-stent strategy

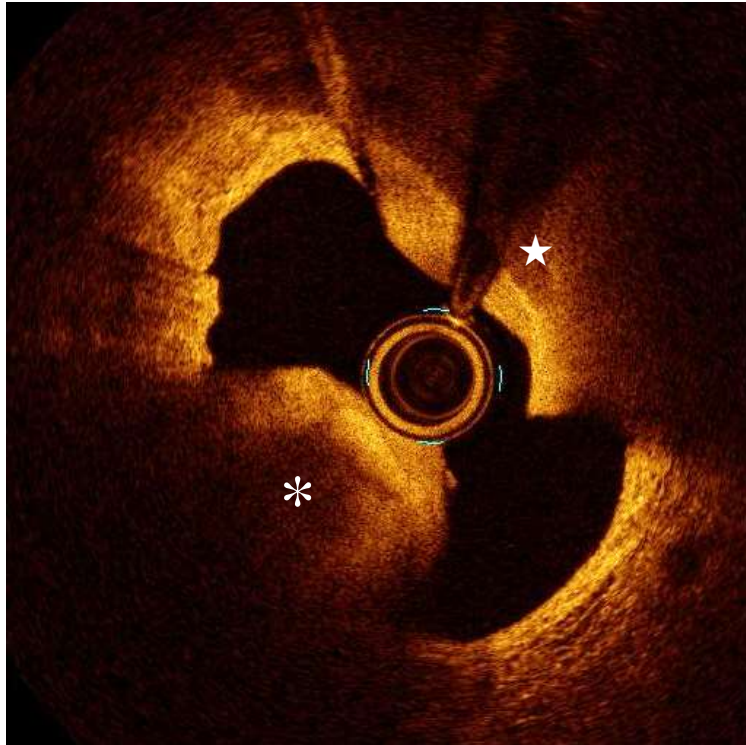


**Case: 27 years old male with STEMI.** Baseline angiogram showed a total occluded lesion in the mid LAD. After thrombus aspiration, residual stenosis on the angiogram at the culprit site was mild (40%). OCT indicated plaque erosion with white thrombus (arrows). After 1 month of treatment with antithrombotic agents, angiogram showed a 30% stenosis, and OCT showed no visible thrombus overlying a fibrous plaque.

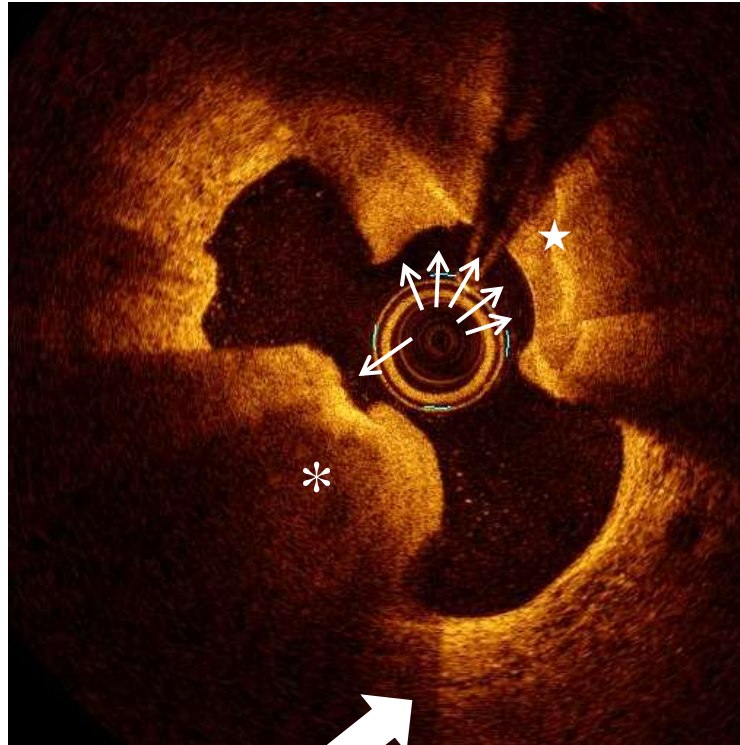

# Ca-nodule: Orbital atherectomy

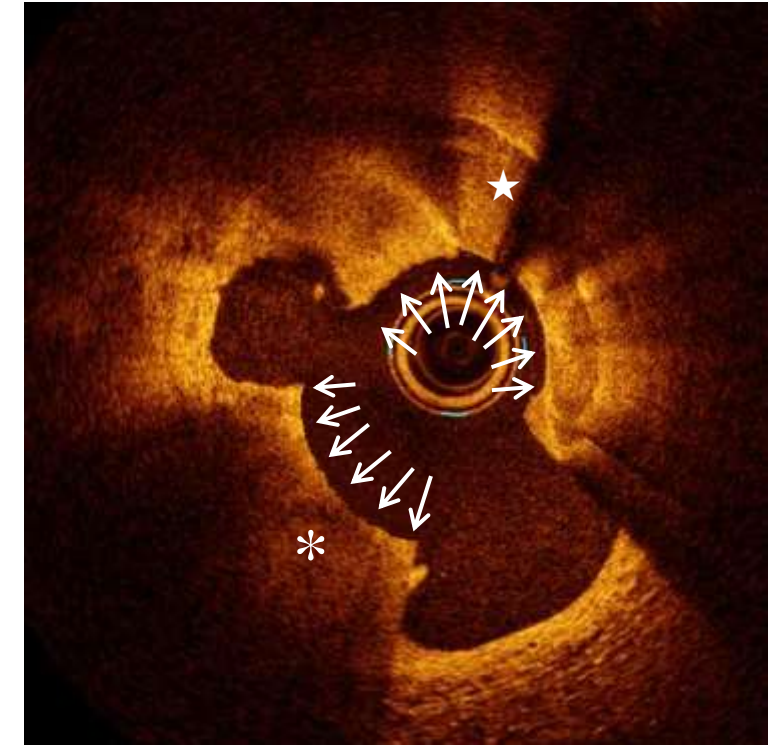
Baseline



1<sup>st</sup> (low speed)



2<sup>nd</sup> (high speed)

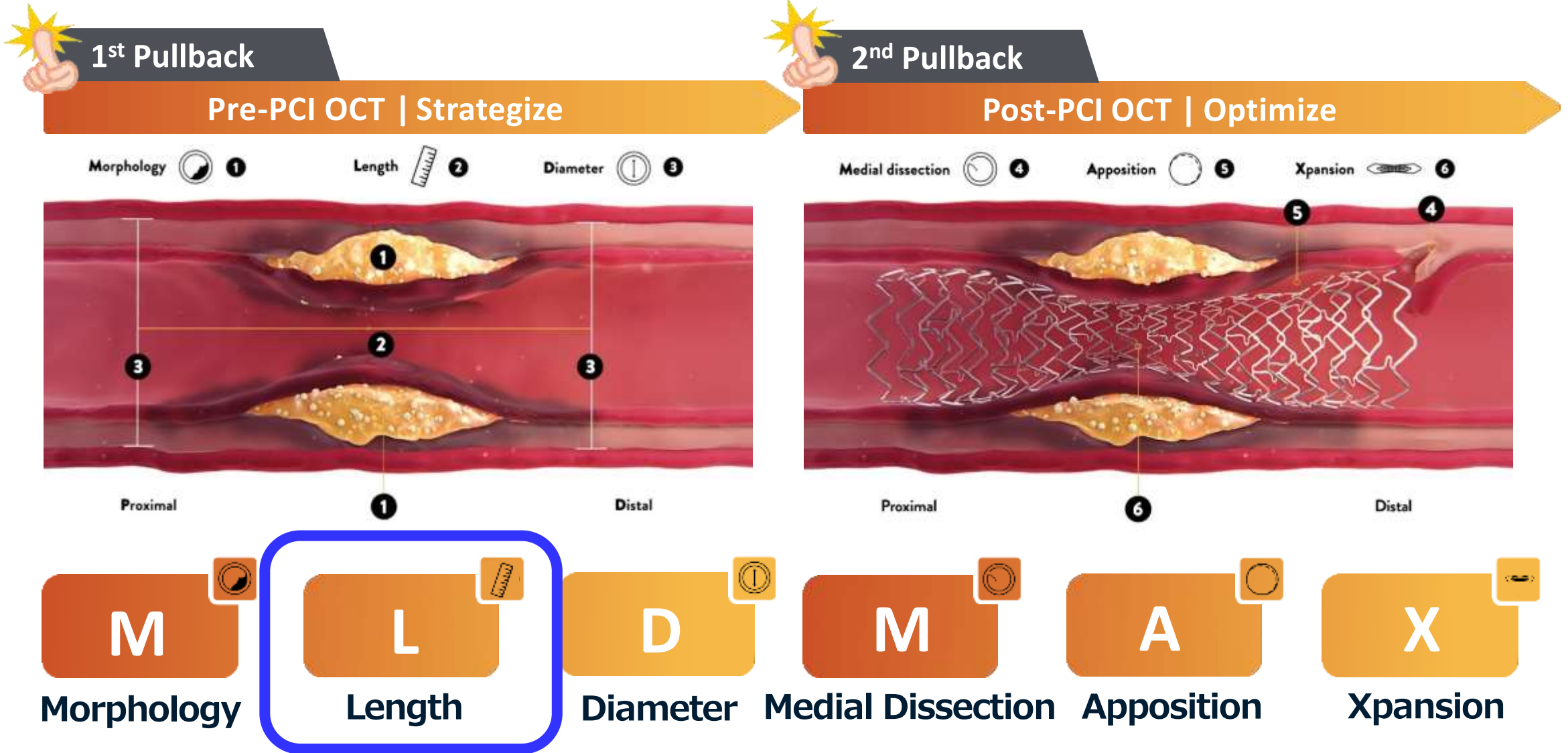


(A) Asterisk = calcified nodule. Star = calcium plate.

(B) Low speed orbital atherectomy ablated mainly calcium plate.

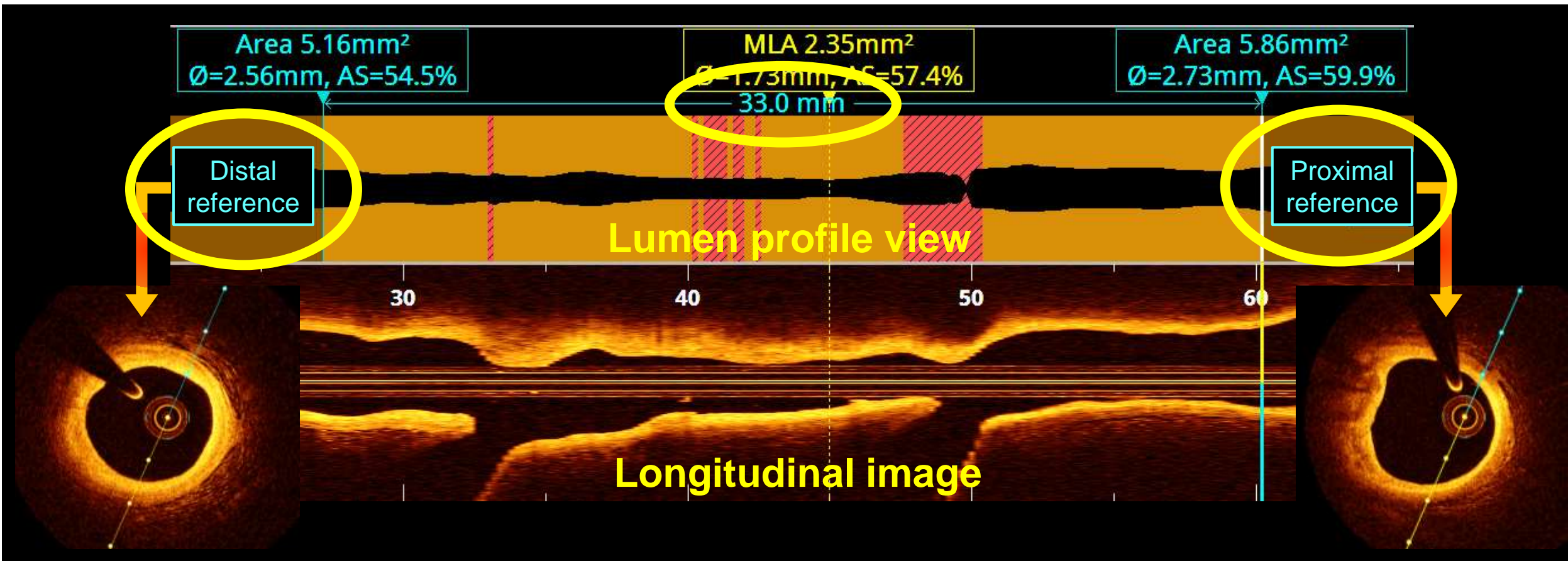
(C) High speed orbital atherectomy ablated was also ablated calcium nodule .

# OCT-guided PCI algorithm **MLD-MAX** 2 Pullback





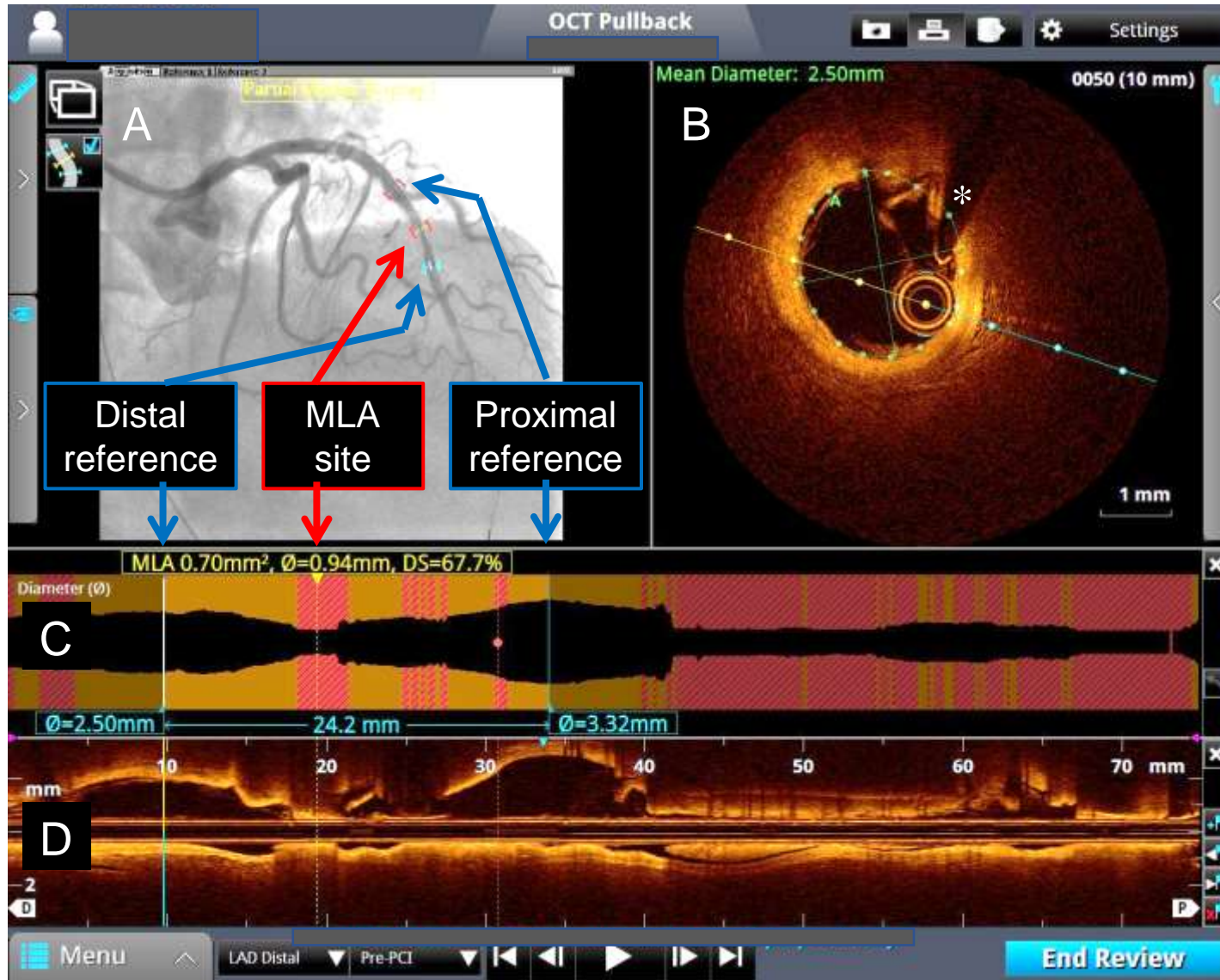
# Reference site and lesion length



- **Reference site:** Most normal looking. Lipid arc <180 degree.
- **Stent length:** By measuring distance from distal to proximal reference site



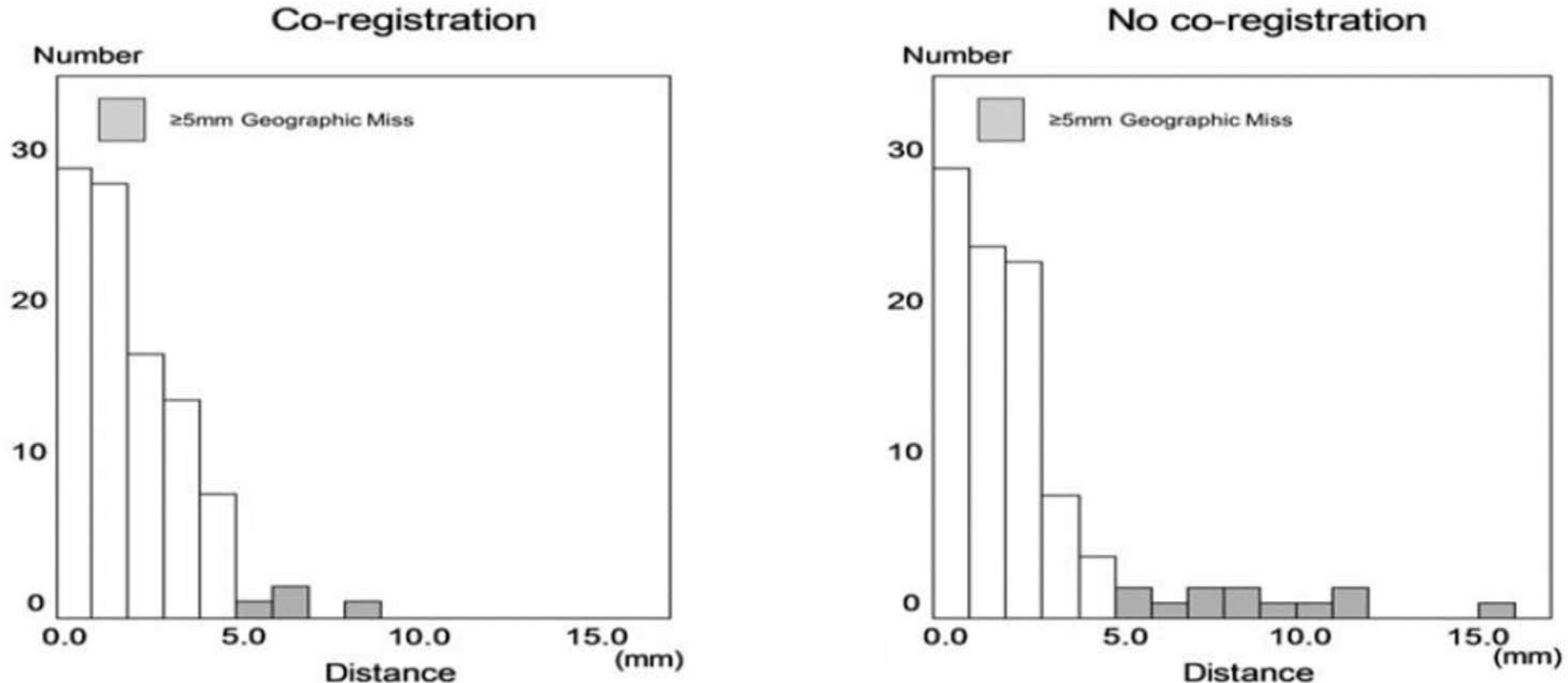
# OCT-Angiography coregistration



- **Angio-coregistration (A)**
  - MLA site
  - Reference sites
  - ⇒ **Geometric miss prevention**
- **Lumen profile view (C)**
  - Automatic measurements
  - Lumen area and diameter
  - ⇒ **Stent size determination**
- **Cross-sectional image (B)**
- **Longitudinal image (D)**

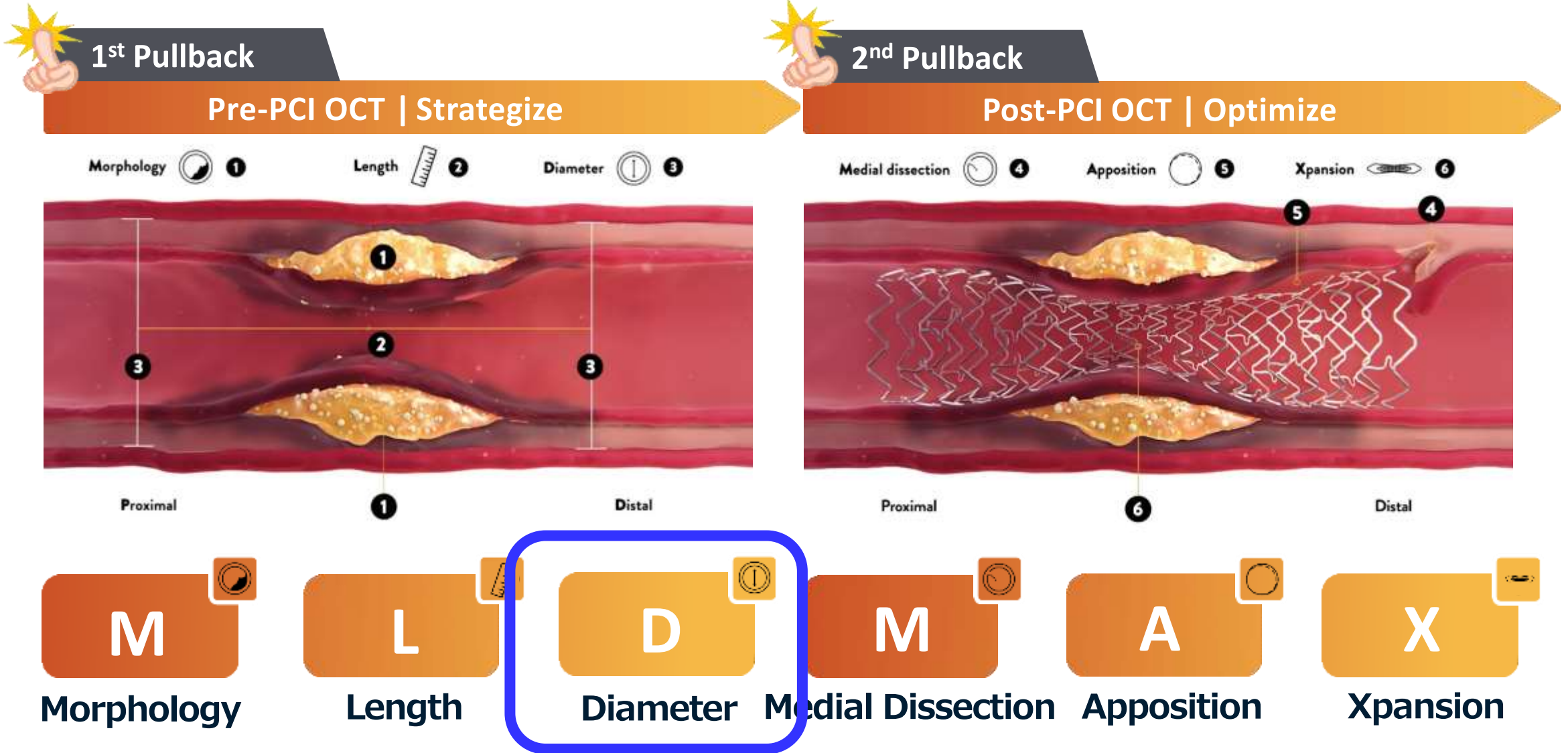
# OCT-Angiography coregistration

**Geographic miss during coronary stenting** was evaluated in OCT-guided PCI with versus without automated OCT-Angiography coregistration in 200 de novo coronary lesions.



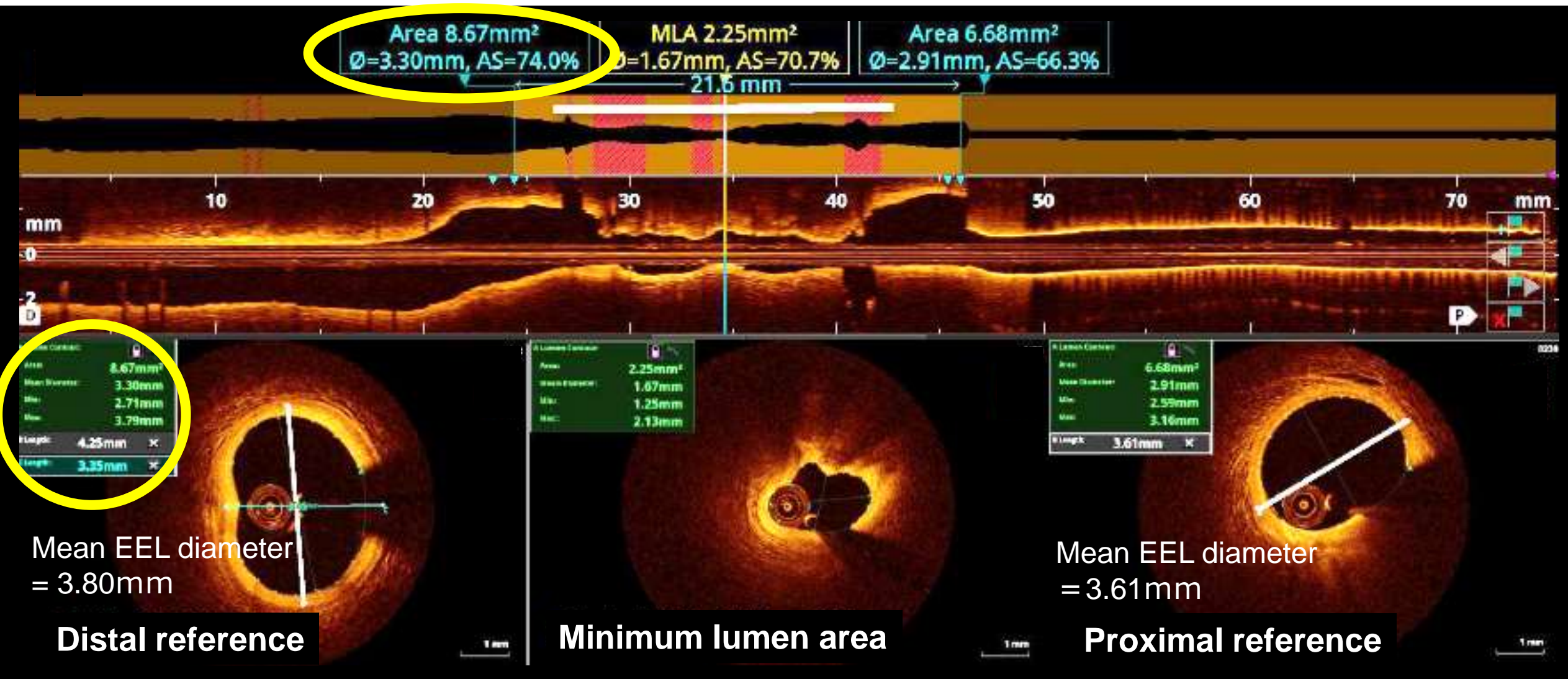
**The discrepancy in the distance between planned vs. actual implanted stent location was significantly shorter in automated OCT-Angiography coregistration use.**

# OCT-guided PCI algorithm **MLD-MAX** 2 Pullback

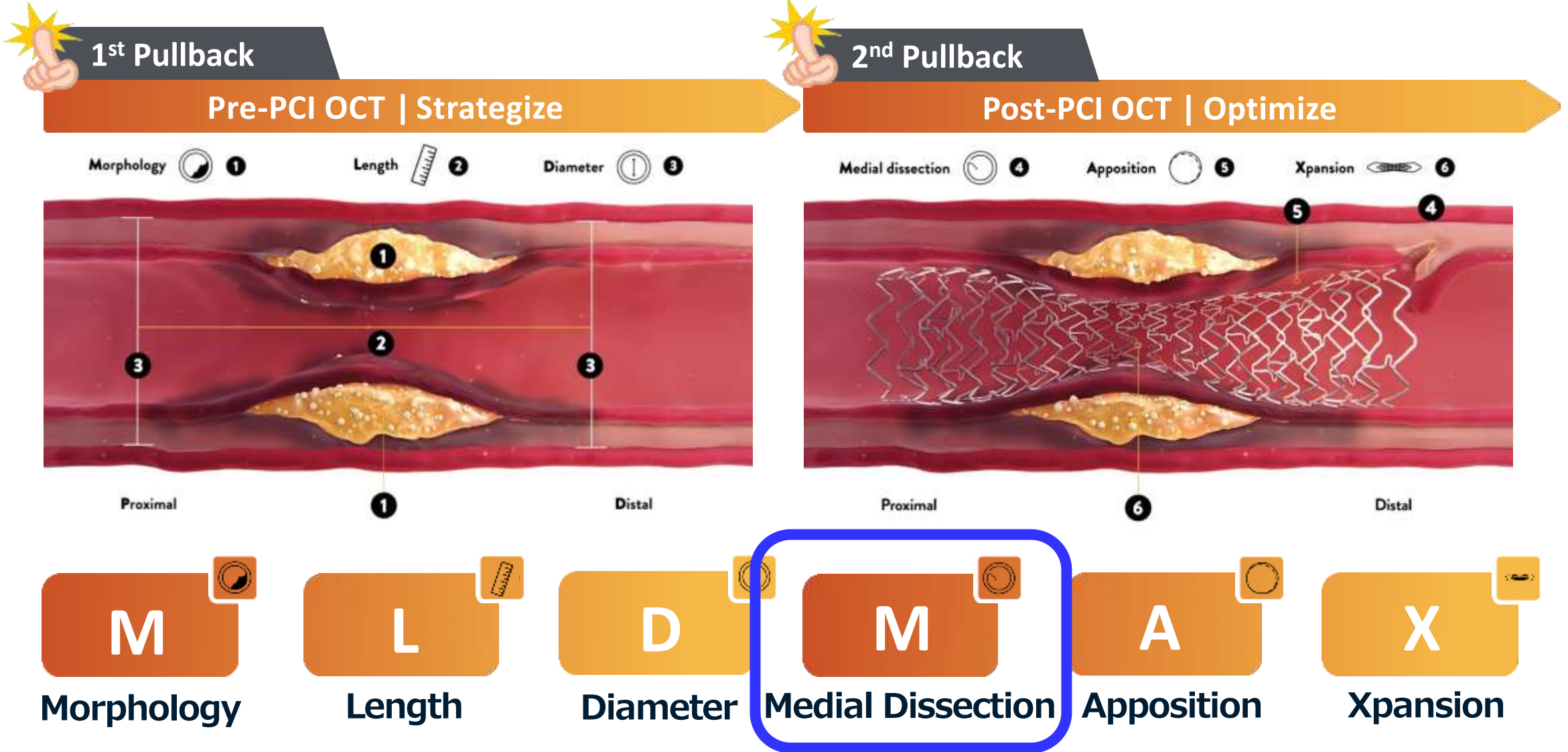




# Determination of stent diameter

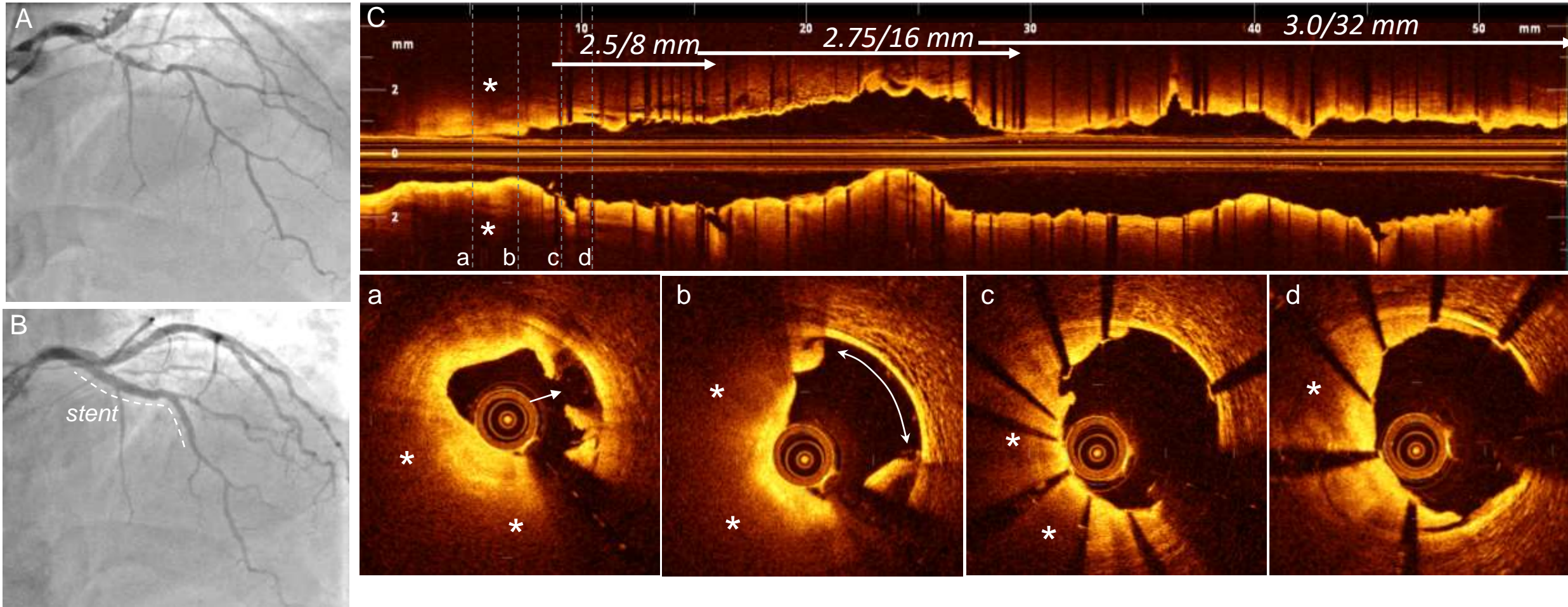


# OCT-guided PCI algorithm **MLD-MAX** 2 Pullback





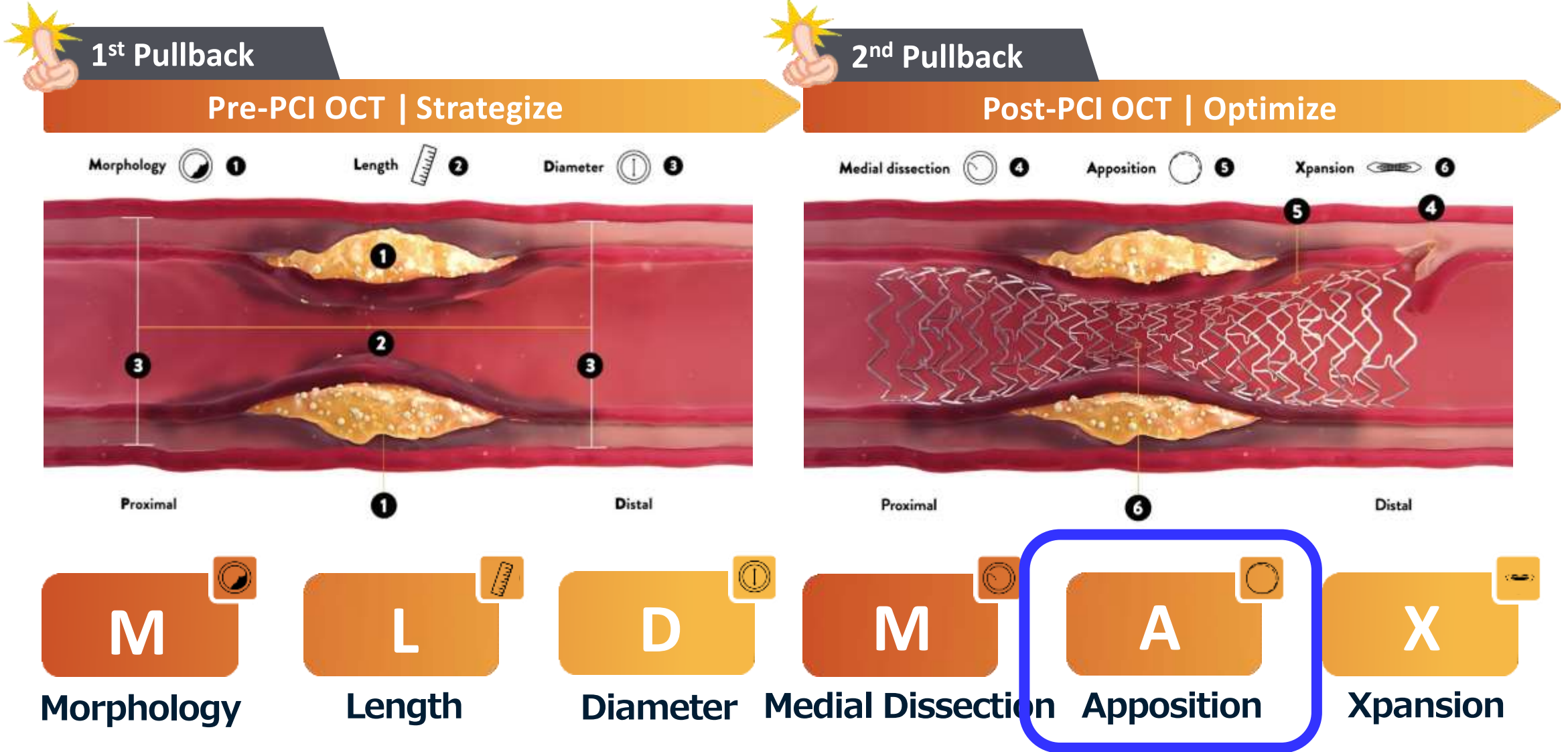
# A case with stent edge dissection



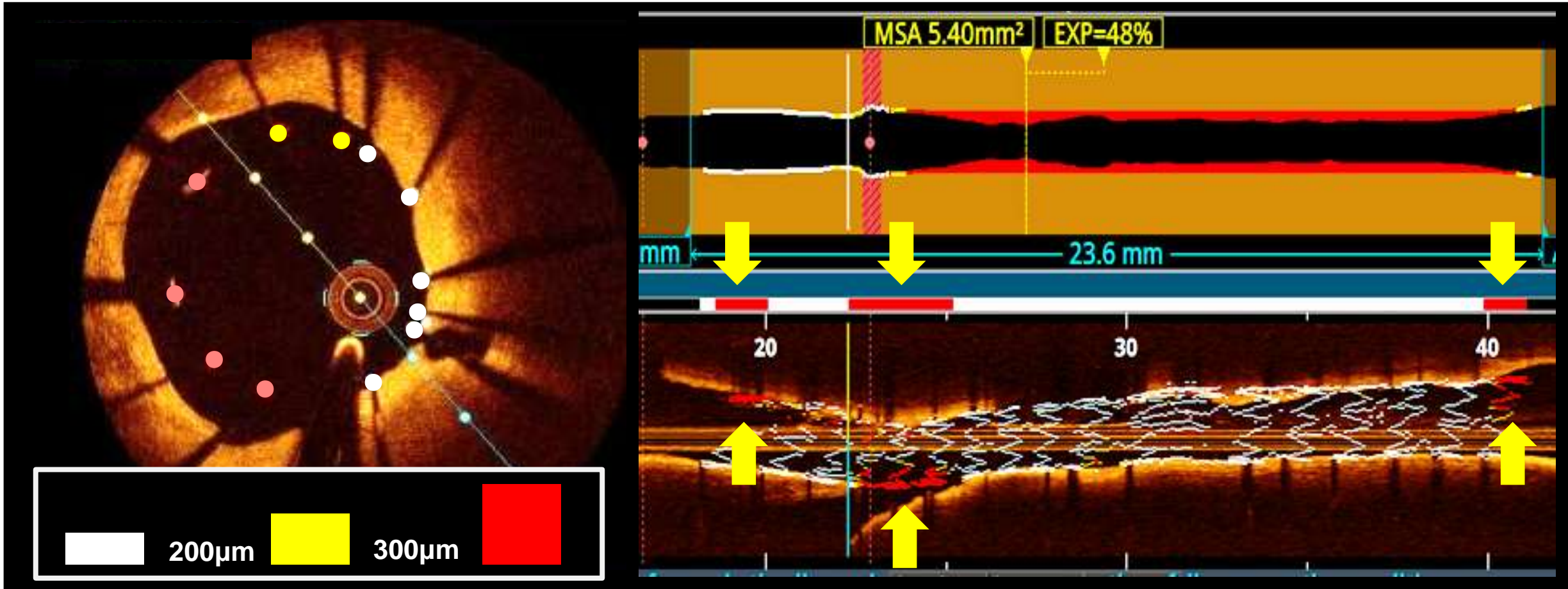
In the OCT short axis image, a and b are similar, and d is fibrous plaque. I think that it is good to present only B and c. A case of stable angina. Coronary angiography showed diffuse severe stenosis in the left anterior descending coronary artery (A). Under the coronary angiography guide, BP-EES 2.5 / 8 mm, 2.75 / 16 mm, 3.0 / 32 mm were placed in an overlapping manner (B). Lipid plaques were observed on the BP-EES 2.5 / 8 mm stent edge in the long axis image (C) of the OCT after stent placement (\*). A short-axis image (ad) corresponding to each level of the long-axis image shows a coronary artery dissection (arrows a and b) spreading on the distal side of the stent and a stent landing on a lipidic plaque (\*) (c, d). 'd' looks like a fibrous plaque.



# OCT-guided PCI algorithm **MLD-MAX** 2 Pullback



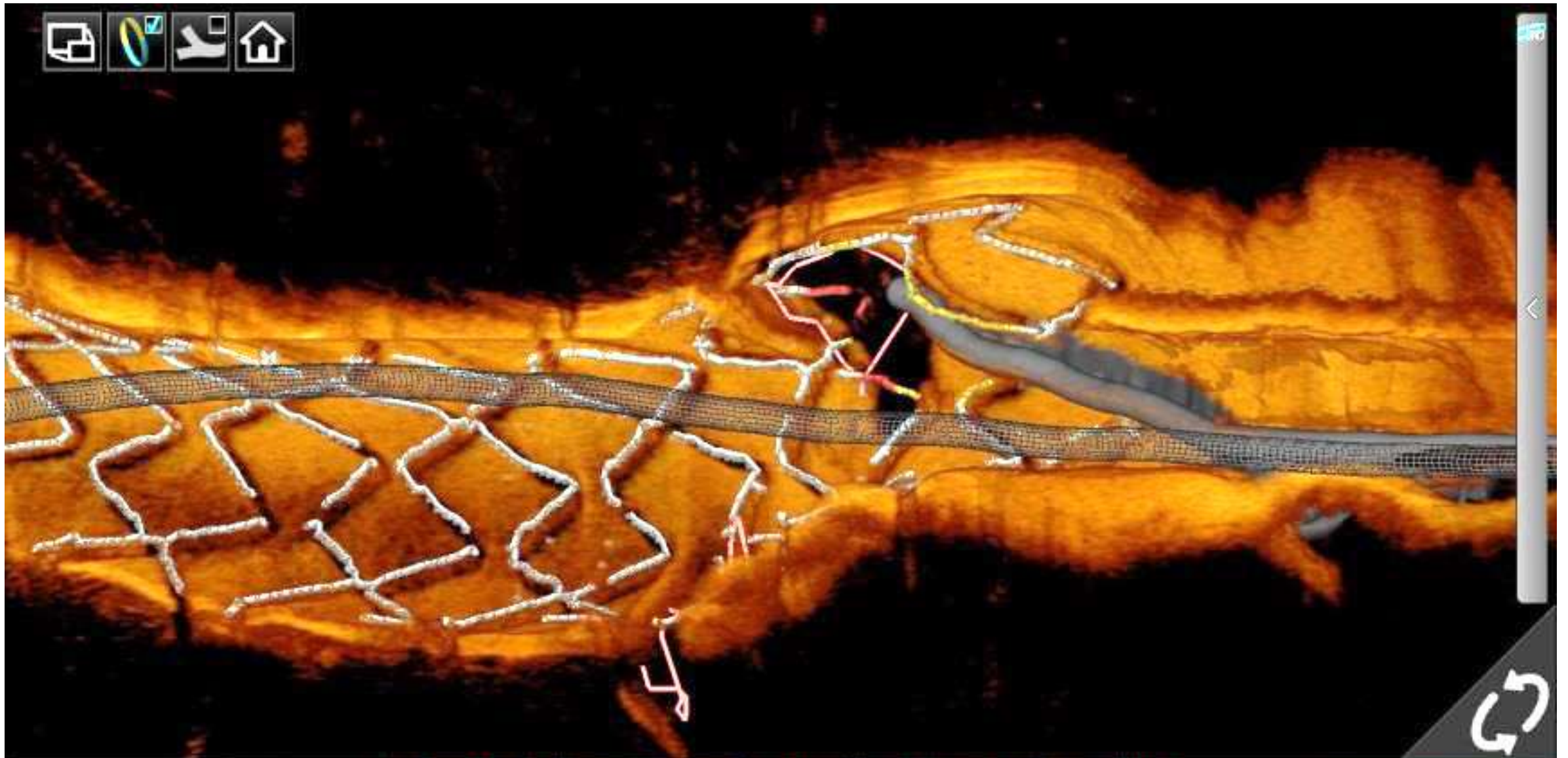
# Stent malapposition



OCT allows automatic detection of malapposed stent struts highlighted by color code. Left = OCT cross-sectional image. Upper = Lumen profile view. Lower = OCT longitudinal view.

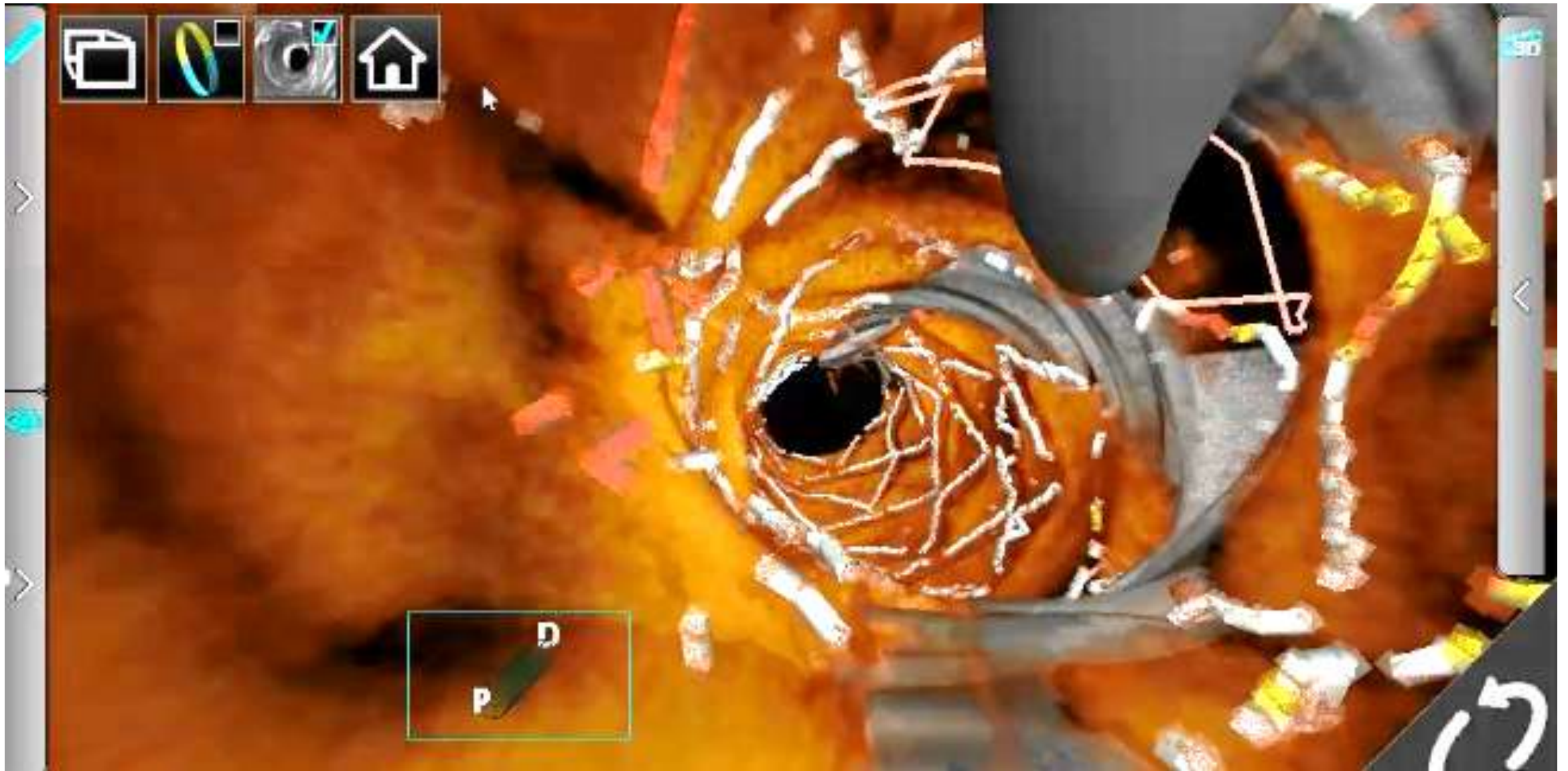


# 3D-OCT image of stent

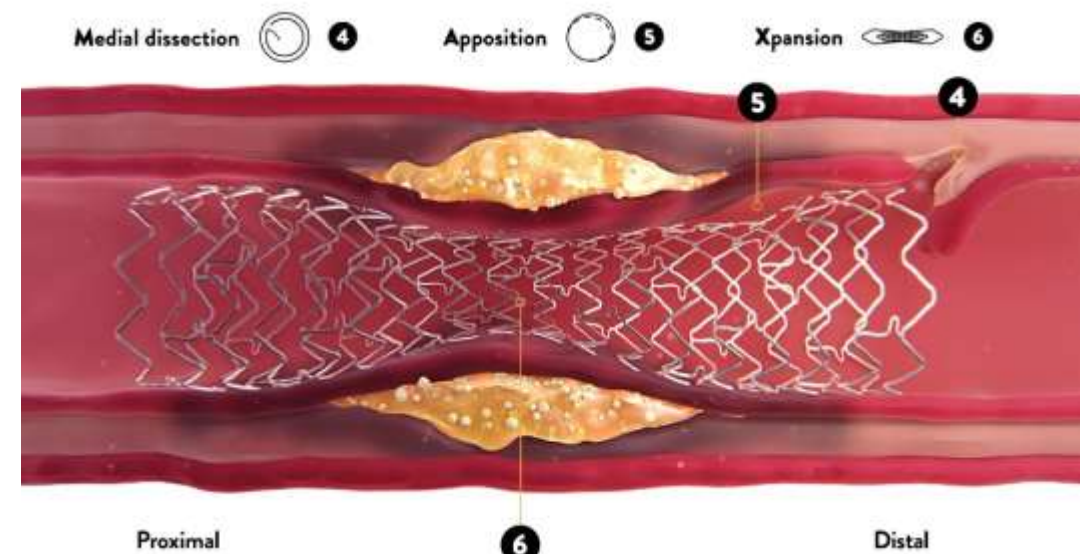
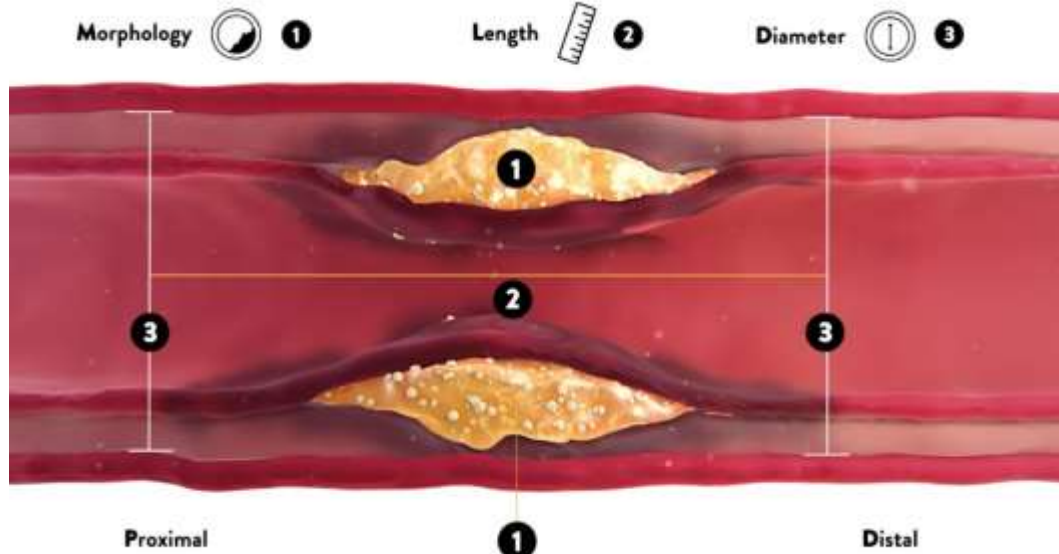




# 3D-OCT image of stent



# OCT-guided PCI algorithm **MLD-MAX** 2 Pullback



**M**  
Morphology

**L**  
Length

**D**  
Diameter

**M**  
Medial Dissection

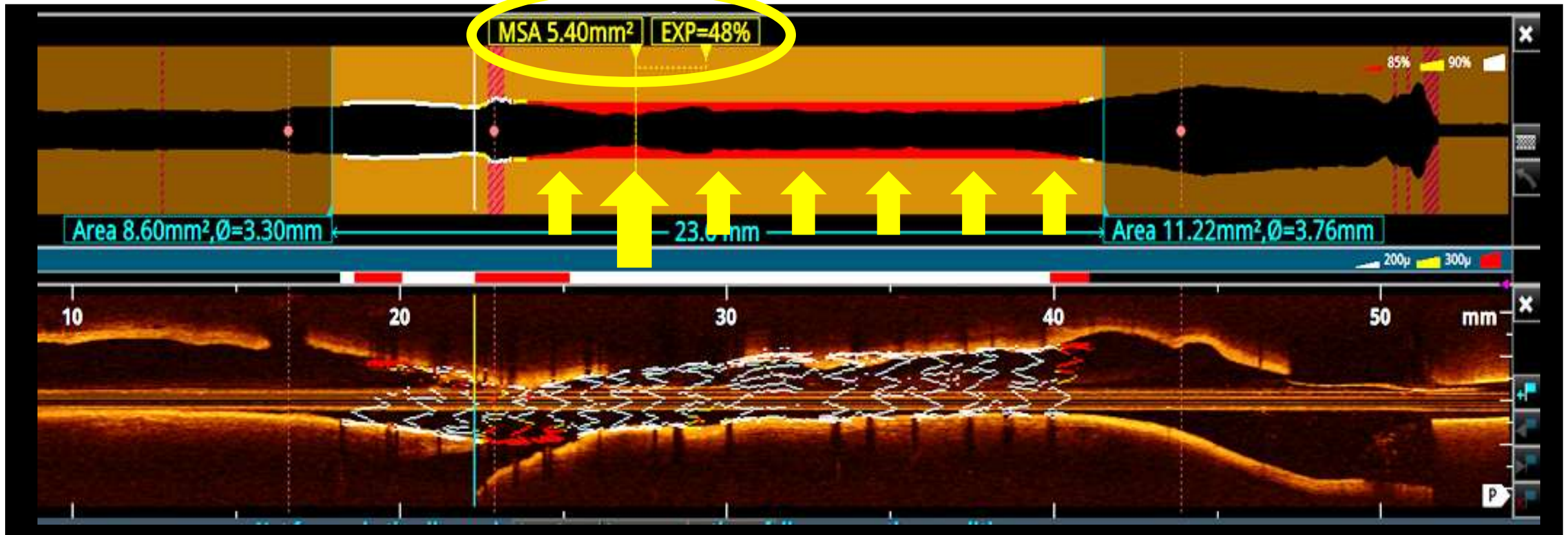
**A**  
Apposition

**X**  
Xpansion





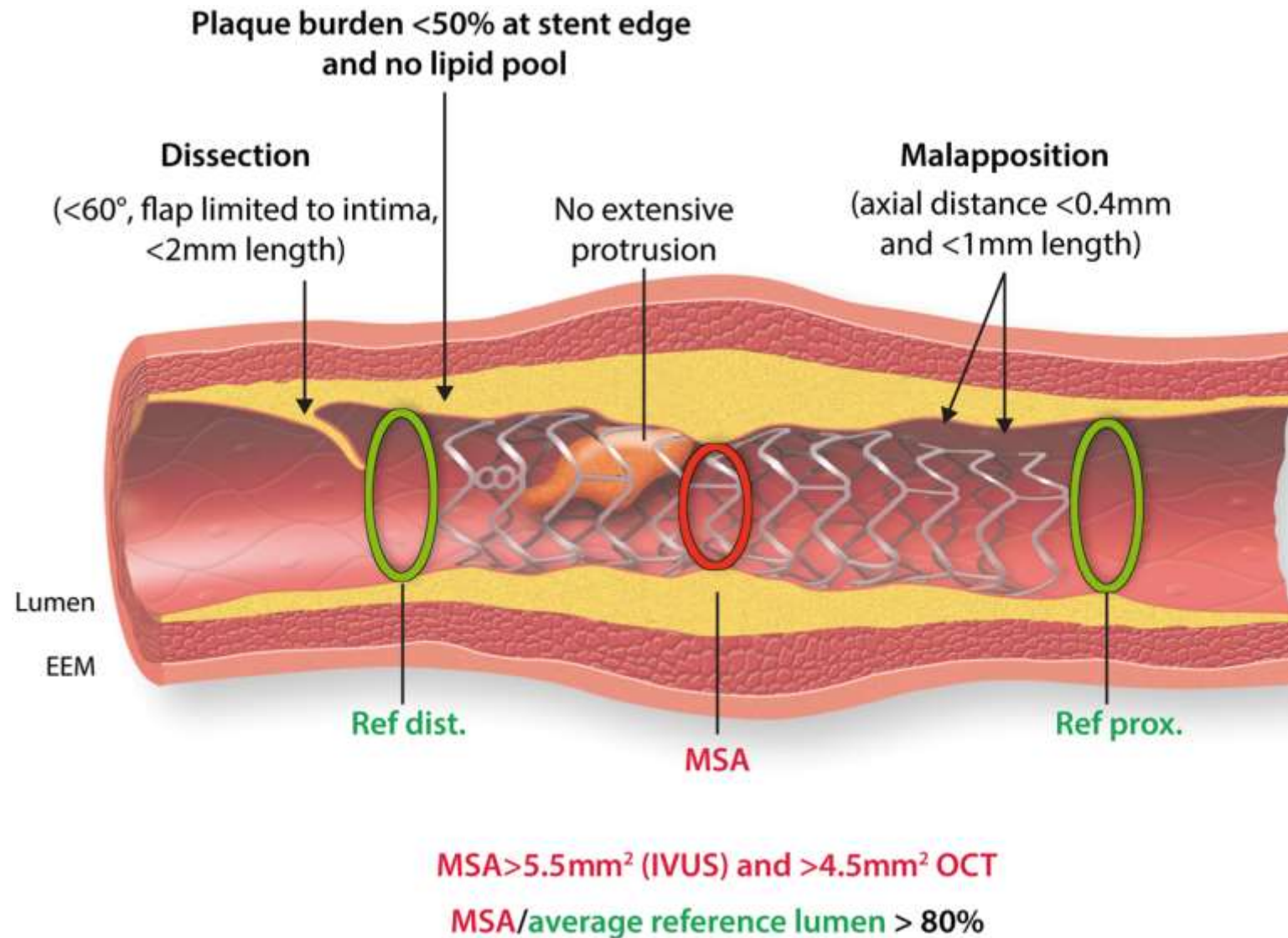
# Stent expansion



OCT allows automatic measurements of minimum stent area (MSA) and stent expansion index (EXP). Upper = Lumen profile view. Lower = OCT longitudinal view.

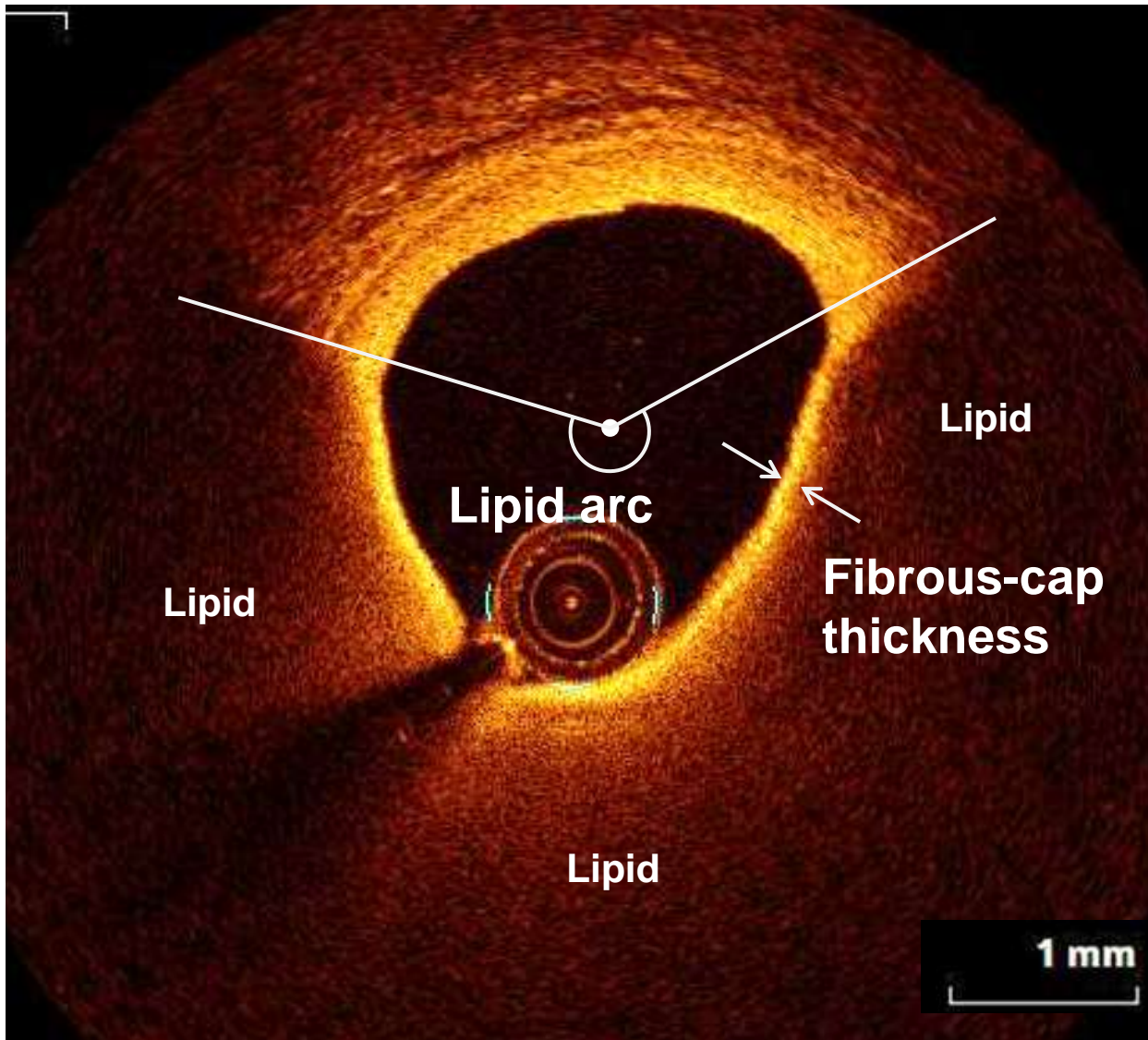


# Summary of post-PCI optimization targets



The most relevant targets to be achieved following stent implantation in non-LM lesions are shown. These include optimal stent expansion (absolute as well as relative to reference lumen diameter); avoidance of landing zone in plaque burden >50% or lipid rich tissue; avoidance of large malapposition regions, irregular tissue protrusion, and dissections. Thresholds provided reflect the consensus of this group. Some are based on consistent and robust prospective data (e.g. stent expansion, landing zone) and others are less established (e.g. malapposition).

# Vulnerable plaque detection: LRP + TCFA



## **Lipid-rich plaque (LRP)**

... Maximum lipid arc  $>180^\circ$

## **Thin-cap fibroatheroma (TCFA)**

... Minimum fibrous cap thickness  $<65 \mu\text{m}$

## **LRP+TCFA**

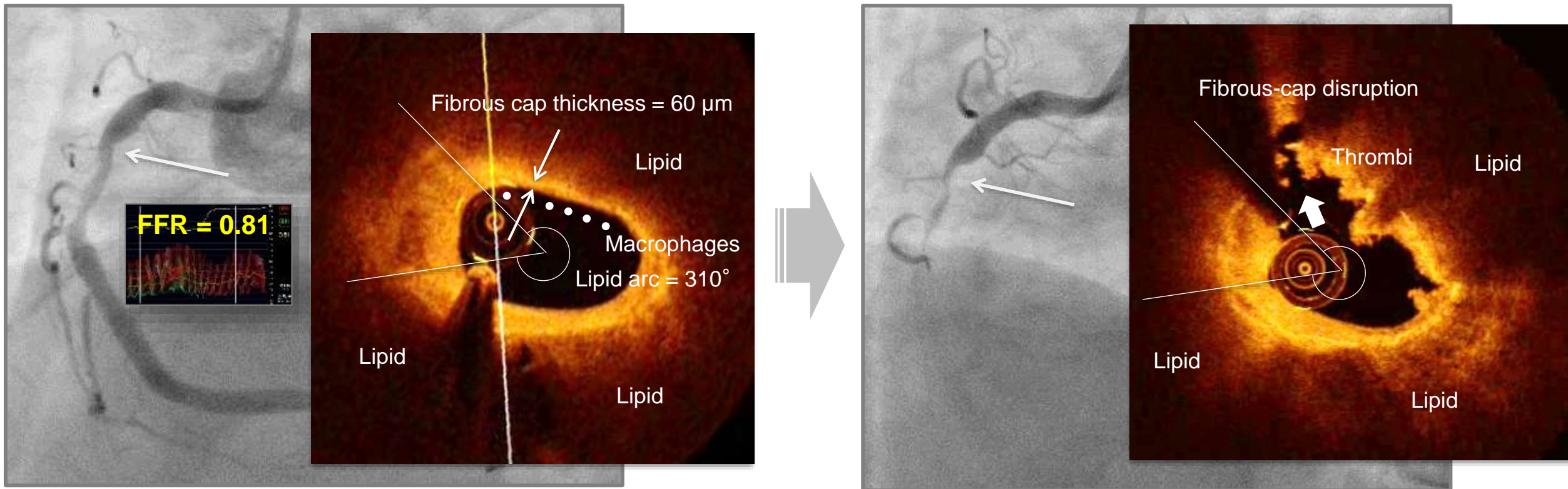
... Meeting both LRP and TCFA definitions



# ACS event arising from LRP+TCFA

Baseline

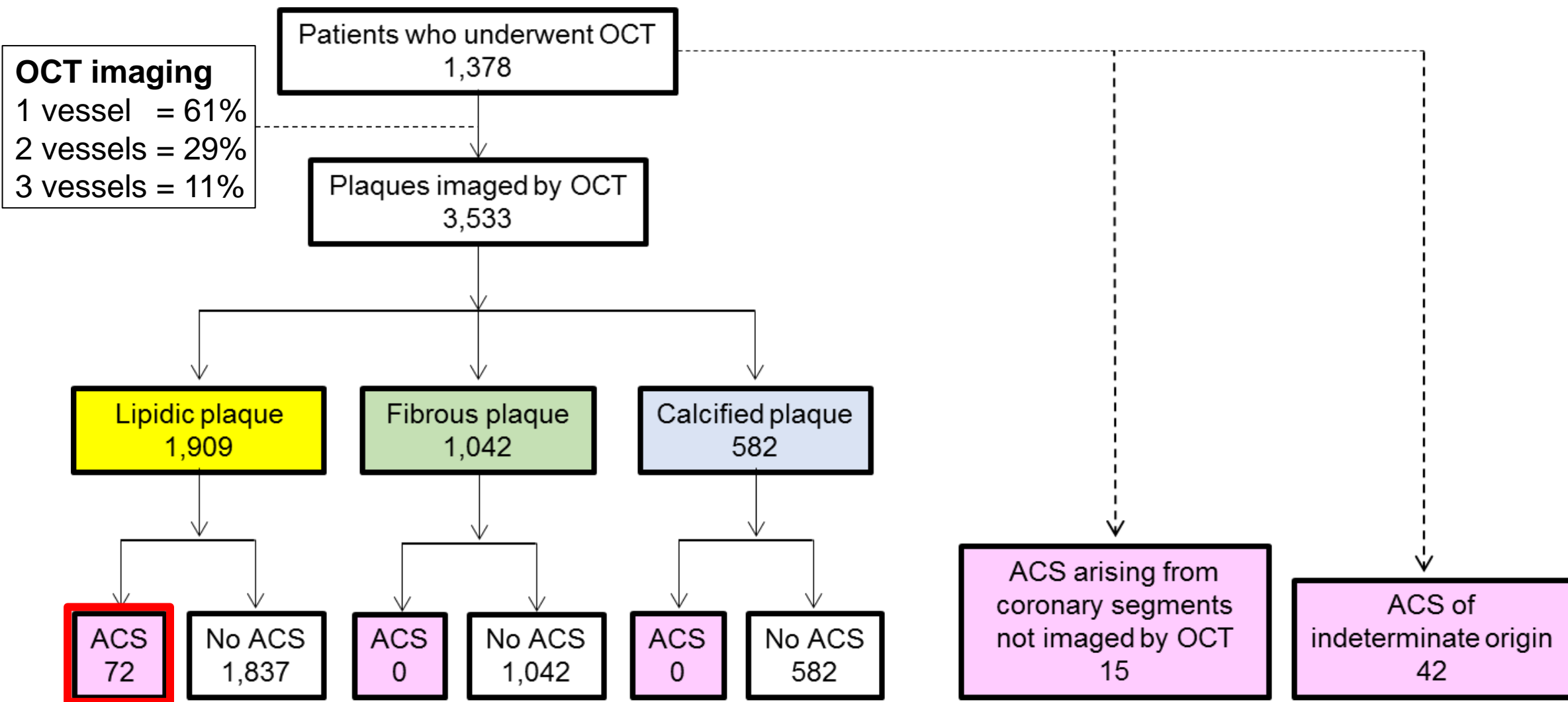
10 months



Baseline angiogram showed moderate stenosis in the proximal right RCA. Baseline OCT characterized the plaque as both LRP and TCFA (maximum lipid arc 310° [asterisks], minimum fibrous cap thickness 60μm [arrow heads], minimum lumen area 2.27mm<sup>2</sup>, and presence of OCT-derived macrophage infiltration [dots]). This plaque was associated with AMI 10 months after baseline imaging. Follow-up angiography showed that the stenosis developed into an occlusion. Follow-up OCT showed rupture (arrow) of the plaque that was imaged during baseline OCT.

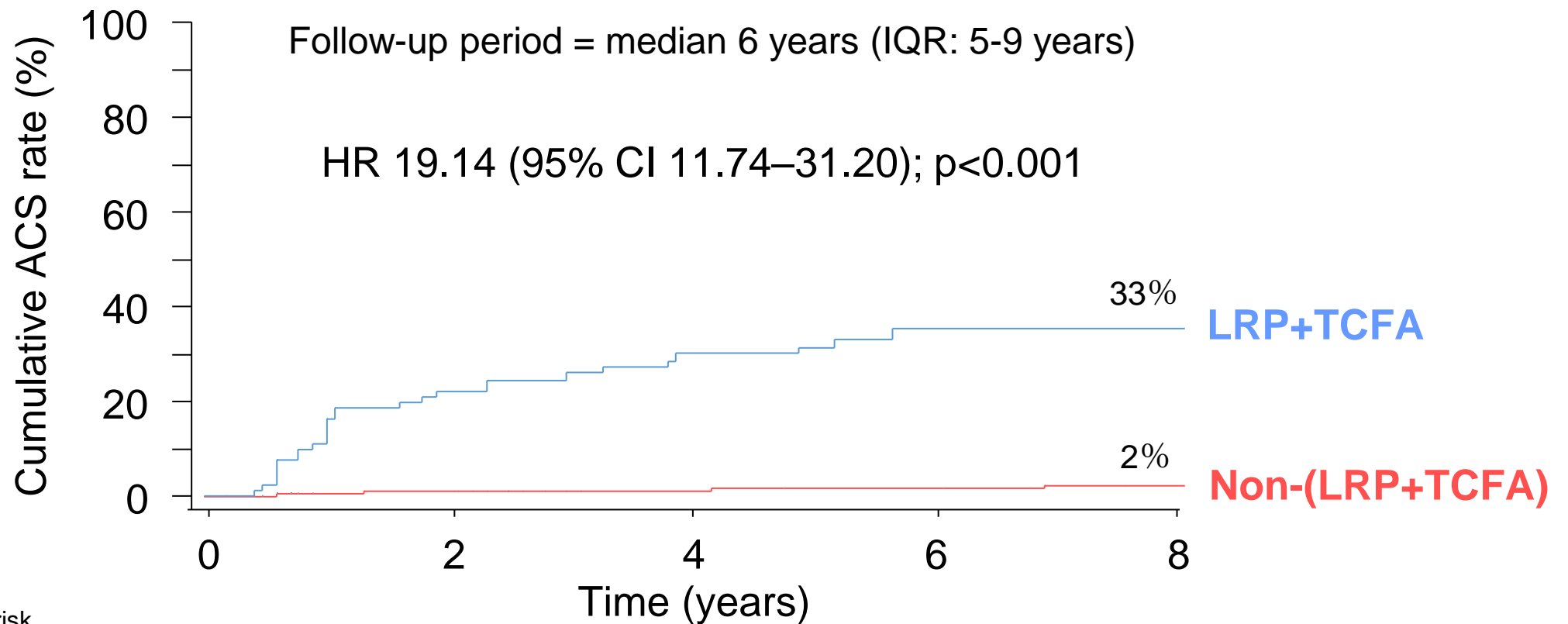


# OCT: Wakayama registry (plaque level analysis)



Follow-up period = median 6 years (IQR: 5-9 years)

# Kaplan-Meier curves



Number at risk

LRP+TCFA

Non-(LRP+TCFA)

83

1,826

63

1,756

50

1,535

27

928

9

532

Lipidic plaques that were characterized as both LRP and TCFA had a significantly higher risk of follow-up ACS than lipidic plaques that did not have those characteristics.

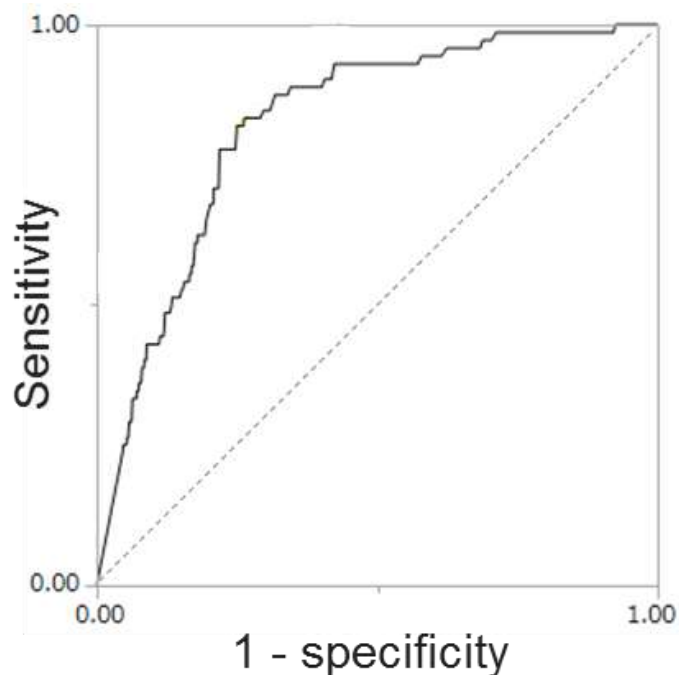
# OCT predictors

	Univariate analysis HR (95% CI)	P	Multivariate analysis HR (95% CI)	P
Max lipid arc	1.01 (1.00-1.01)	<0.001	1.01 (1.01-1.01)	<0.001
Lipid length	1.03 (0.98-1.08)	0.193	-	-
Min fibrous-cap thickness	0.98 (0.98-0.99)	<0.001	0.99 (0.98-0.99)	<0.001
Macrophages	4.83 (2.80-8.34)	<0.001	1.06 (0.58-1.95)	0.850
Microvasculature	0.72 (0.38-1.38)	0.324	-	-
Cholesterol crystal	0.97 (0.50-1.89)	0.925	-	-
Min lumen area	0.73 (0.63-0.84)	<0.001	0.78 (0.67-0.90)	<0.001

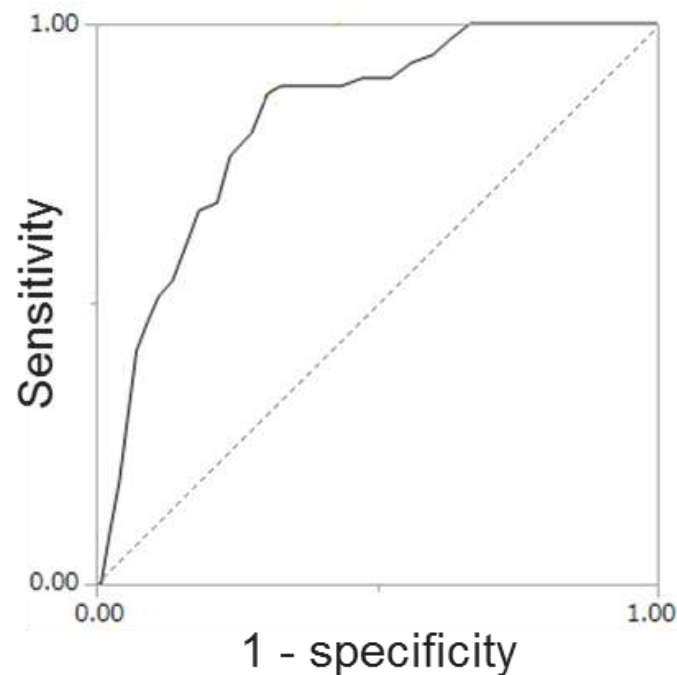


# Optimal cutoffs to predict ACS

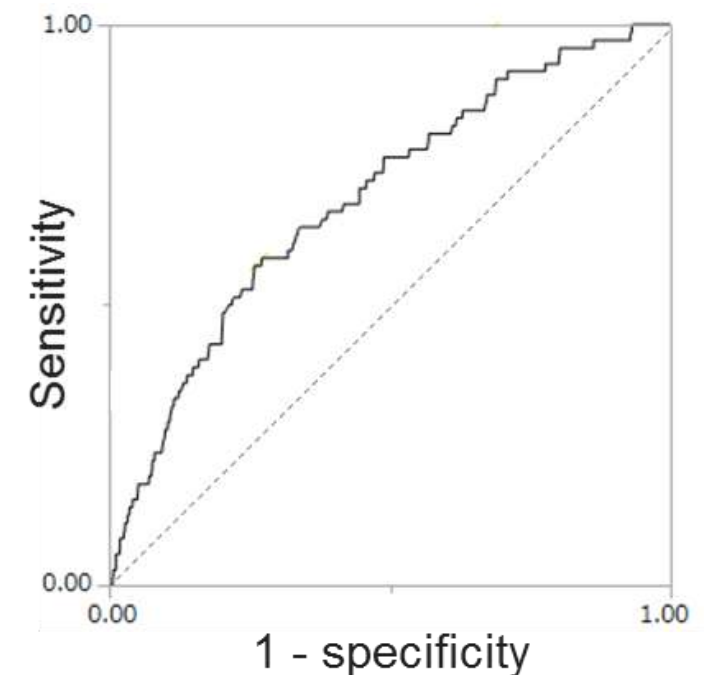
**Maximum lipid arc**  
**Cut-off  $\geq 185^\circ$**   
**AUC = 0.82**



**Minimum fibrous cap thickness**  
**Cut-off  $\leq 150\mu\text{m}$**   
**AUC = 0.83**

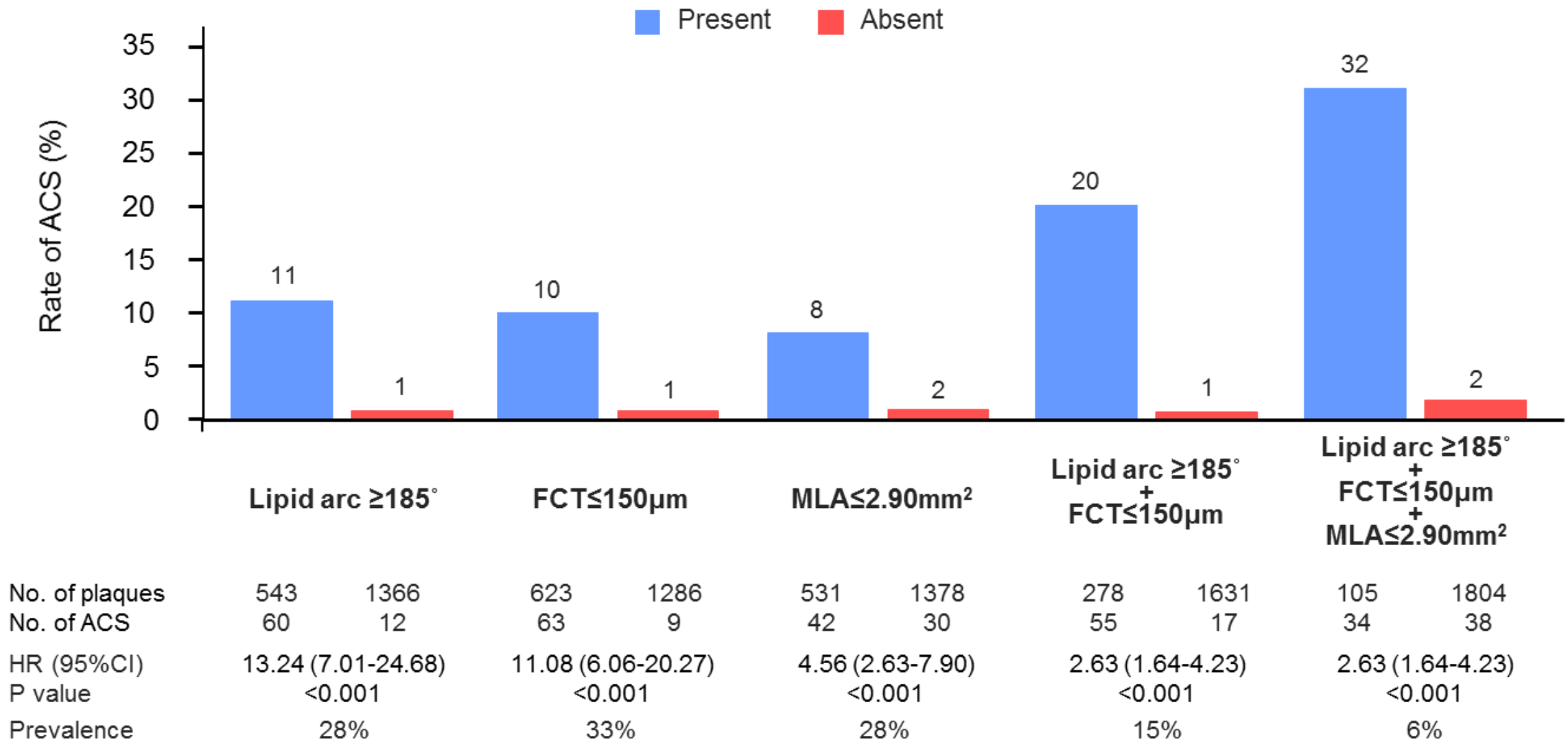


**Minimum lumen area**  
**Cut-off  $\leq 2.90\text{mm}^2$**   
**AUC = 0.69**



Based on ROC curve analysis, the optimal cutoffs to predict ACS were maximum lipid arc of  $\geq 185^\circ$ , minimum fibrous cap thickness of  $\leq 150\mu\text{m}$ , and minimum lumen area of  $\leq 2.90\text{mm}^2$ .

# Positive predictive value for ACS



# Conclusion

- OCT is useful to guide PCI, especially for stent sizing and stent optimization.
- OCT can be used to identify non-culprit (i.e. non-flow limiting) vulnerable plaques at high risk for future events.







# Thank you!